

# Head and Neck Anatomy

*Yang Chai, DDS, PhD*

*University Professor*

*George and MaryLou Boone Chair  
in Craniofacial Biology*

*Ostrow School of Dentistry USC*

*Mikel Snow, PhD*

*Professor*

*Ostrow School of Dentistry  
Keck School of Medicine  
USC*

June 24, 2024

## 2024 TEACHING INSTRUCTORS

### HEAD & NECK ANATOMY



**Dr. Yang Chai**  
ychai@usc.edu



**Dr. Mike Snow**  
mikelhes@usc.edu



**Dr. Mahsa Alavi**  
mahsaa@ostrow.usc.edu



**Dr. Peng Chen**  
pc\_856@usc.edu



**Dr. Wren Edwards**  
wren.edwards@usc.edu



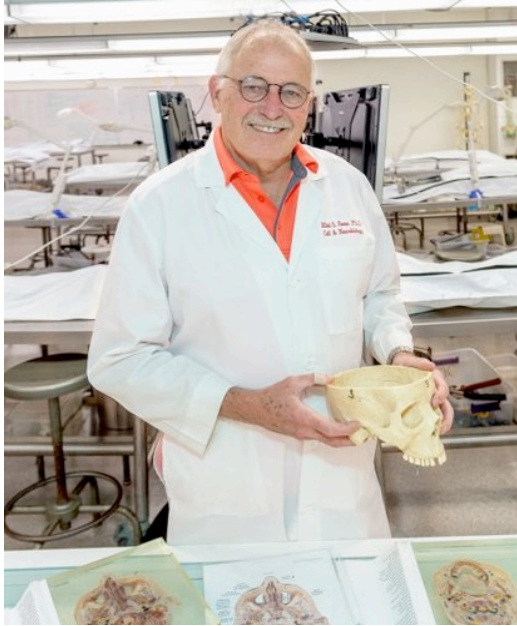**Dr. Pedro Sanchez**  
pedro.sanchez.md@gmail.com



**Dr. Zana Sims**  
zsims@usc.edu



# Dr. Mikel Snow



[mikelhes@usc.edu](mailto:mikelhes@usc.edu)

# 2024 TEACHING ASSISTANTS

## HEAD & NECK ANATOMY



**Ray Bernal**  
rdbernal@usc.edu



**Jaynelle Gao**  
jaynellg@usc.edu



**Kaitlin Hori**  
khori@usc.edu



**Sarah Jivraj**  
sarahjiv@usc.edu



**Mike Kim**  
kimmi@usc.edu



**Cecilia Solis**  
solisave@usc.edu



**Angela Tang-Tan**  
tangtan@usc.edu



**Jose Ubeda**  
ubeda@usc.edu



**Sahiti Vemula**  
vemula@usc.edu



**Ariel Vieira**  
arielvie@usc.edu



**Talia Wenger**  
tawenger@usc.edu

# Course format

1. Lectures at 1:00pm every Monday and **1:30pm every Wednesday**
2. Laboratory dissection sessions with TAs and faculty
3. Review sessions with TAs in the lab on July 6-7, 2024 (before midterm exam) and July 27-28, 2024 (before final exam)

Anatomy Lab access code: 11111

Start-1111-lower right key



**Authorized people only**




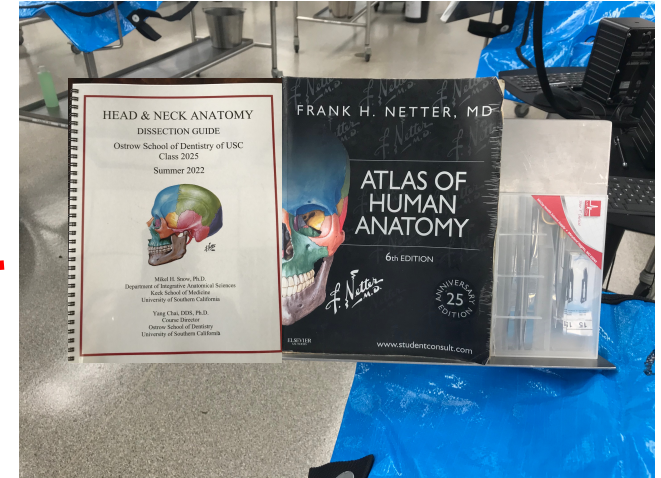

# Dissection Group # = Table #

Table #

STUDENT COPY

DISSECTION GROUPS  
2023

Last Name	First Name	Dissection Group
Abdah	Dana	21-STEPHANIE
Abdallah	Elaina	11-NICOLAS
Addagatia	Gaurav	13-RYMOND
Adorbehi	Parsa	1-DARA
Al Rasheed	Marah	15-SHAUN
Alsharifi	Abdullah	3-ARIEL
Amin	Michael	9-MAYLIS
Asabor	Eugene	7-JOLIE
Aslanian	Alina	19-TYLER
Aslanyan	Michael	7-JOLIE
Avedian	Sion	21-STEPHANIE



## *How to use these three different containers in the laboratory*



**Excised  
tissues (skin,  
fascia, fat,  
bone, etc.)  
It must stay  
with the donor**



**Place used  
gloves and any  
paper toweling in  
contact with  
donor  
tissues/fluids in  
this container**



**Disposal of  
Non-biohazardous  
Materials**

**1. All PPTs can be downloaded at**  
**<https://ccmb.usc.edu/resources/teaching-resources/> & **Dropbox****

**2. Head and Neck Dissection Guide (PDF file)/Available on the computer screen in the lab**

**3. Learning objectives in course syllabus**

**4. Study Guide for each session**

**5. Check-lists for midterm and final examinations**

# Dissection Videos

<https://vimeo.com/showcase/7264128>

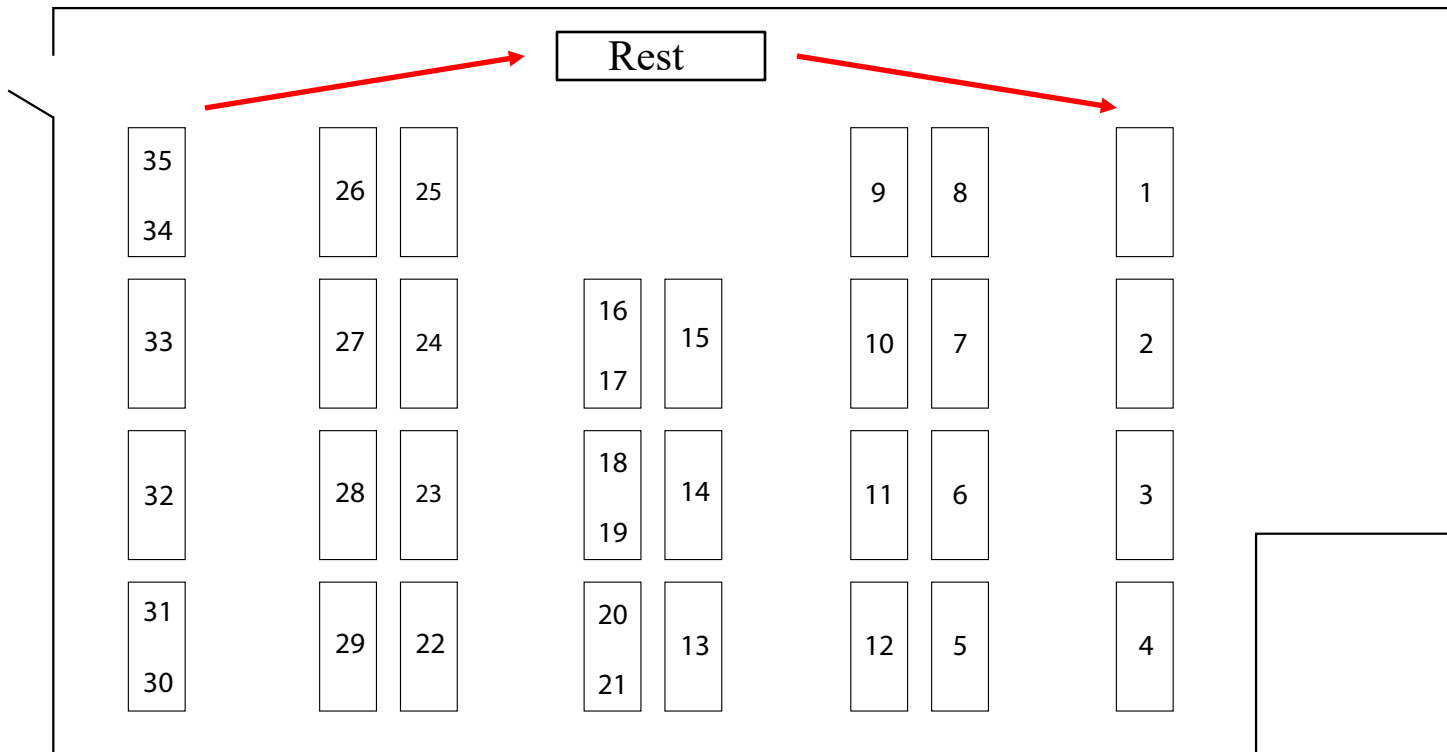
Password: HeadNeckVideos



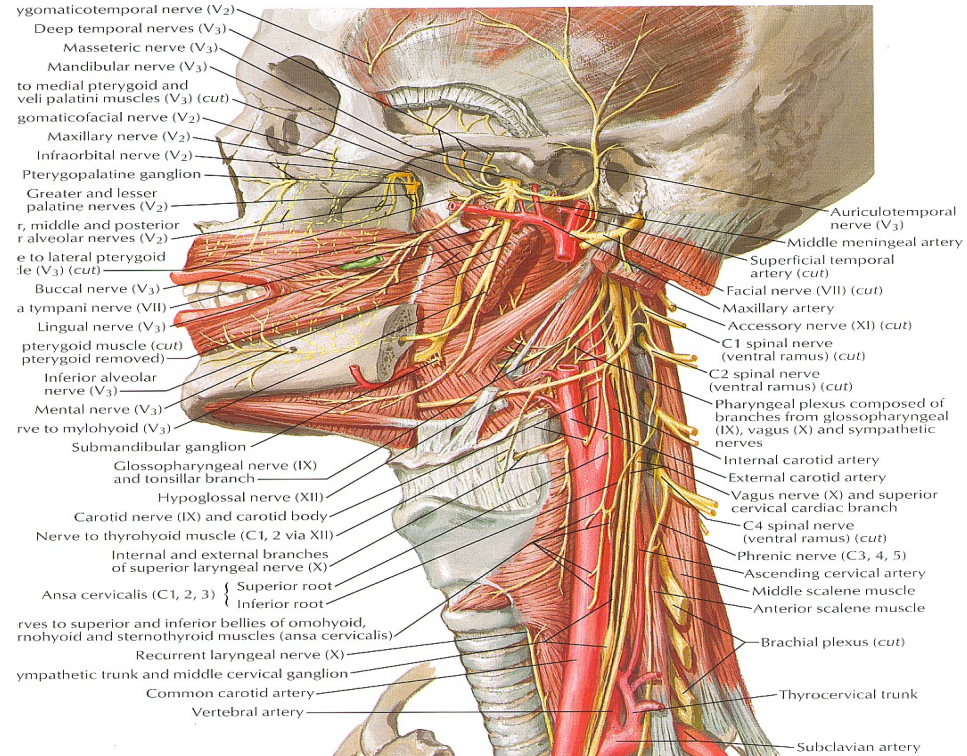
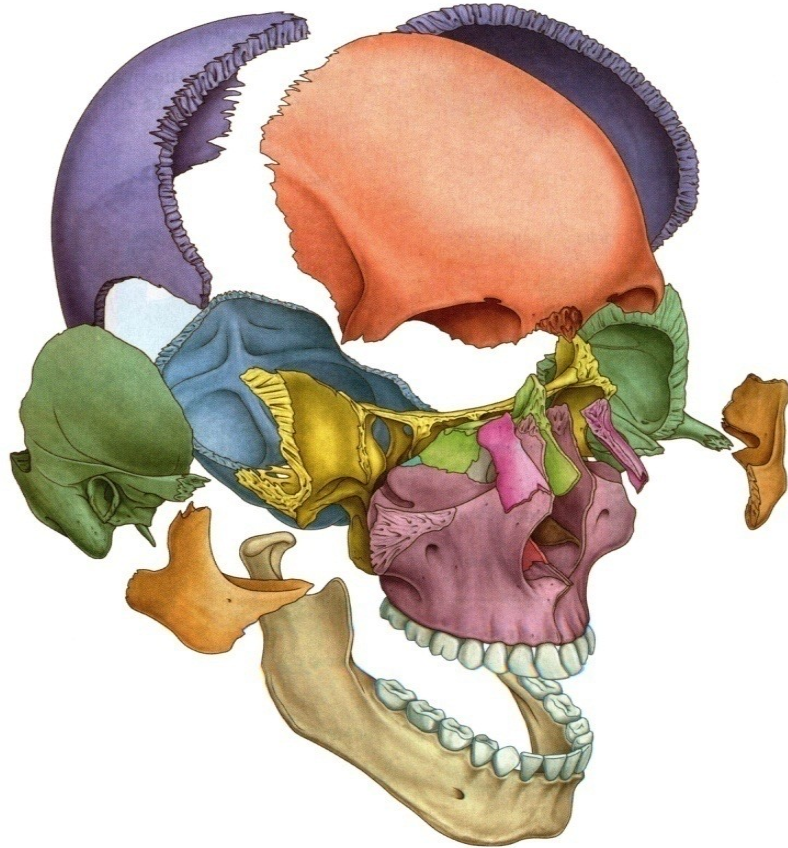
# Examinations

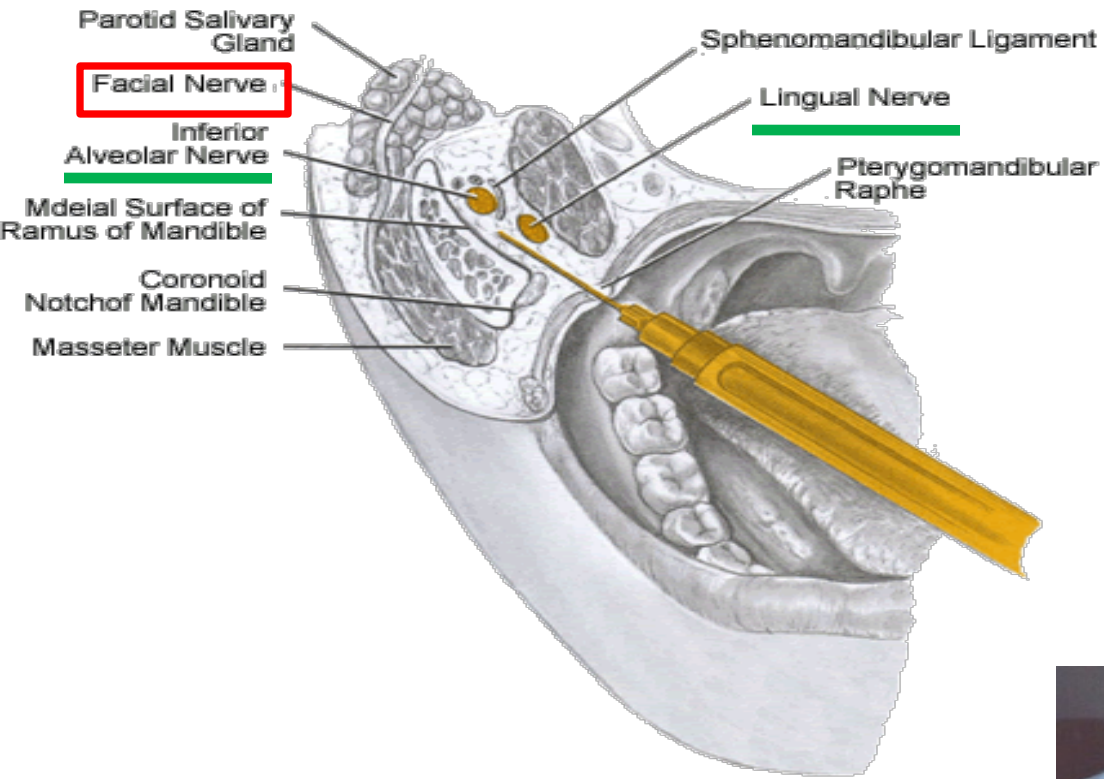
- Midterm Examination (Anatomy lab)  
July 10, 2024
- **Comprehensive** Final Examination  
(Anatomy lab) July 29, 2024

# Lab examination set up



# Head and Neck Anatomy





# *Mandibular block and potential clinical complications*

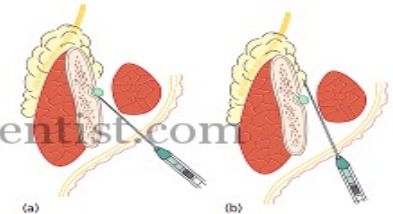
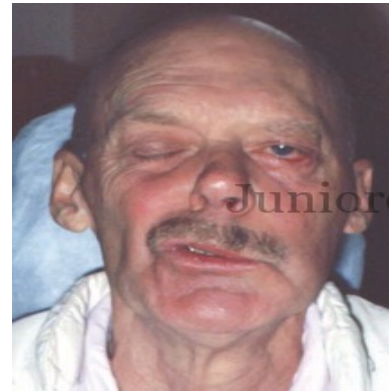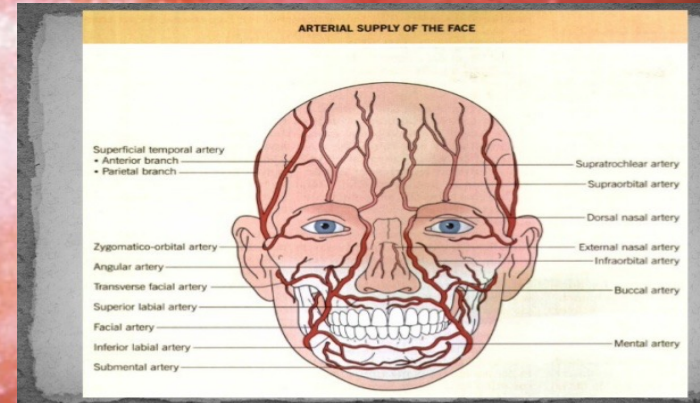

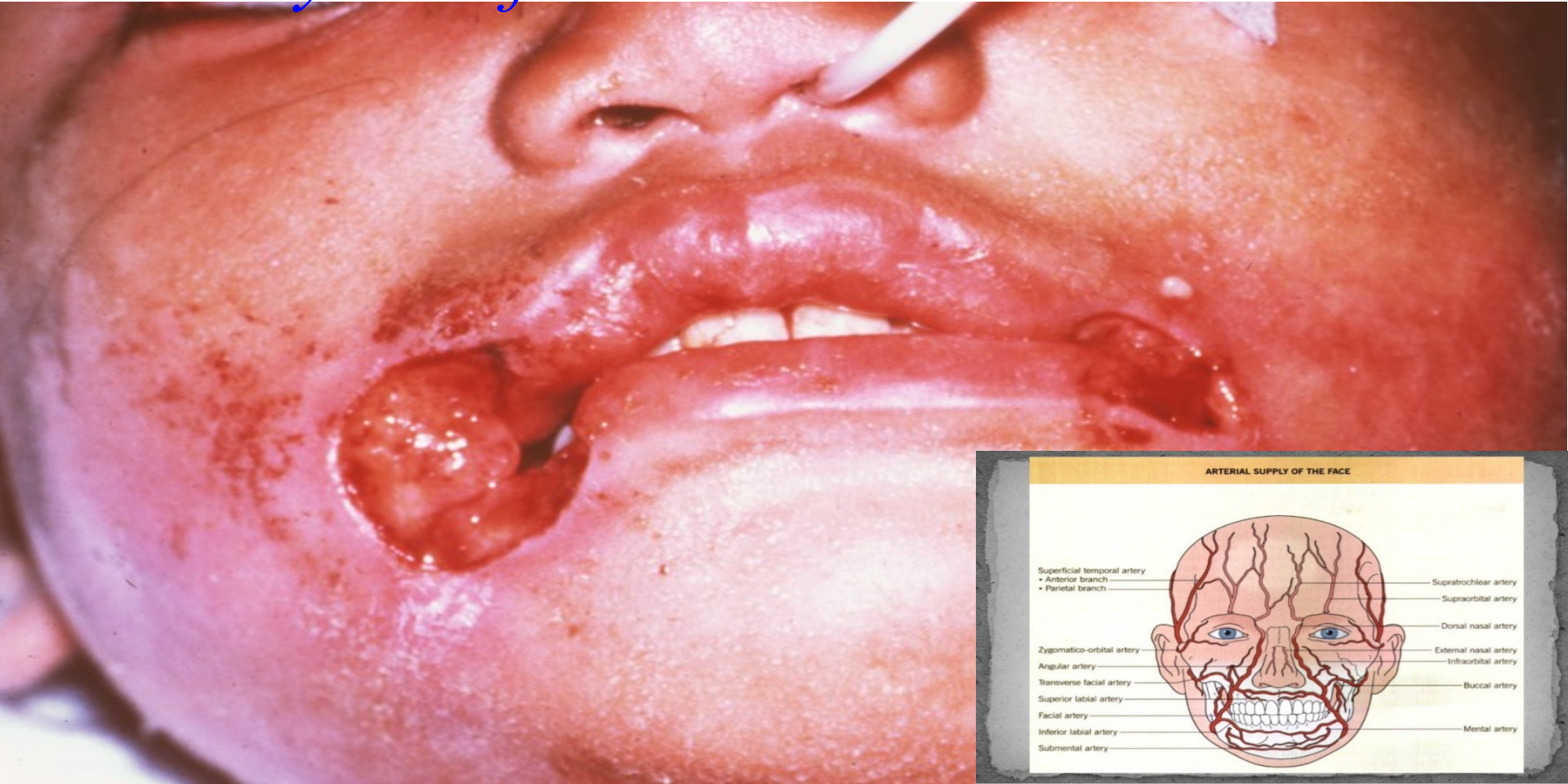
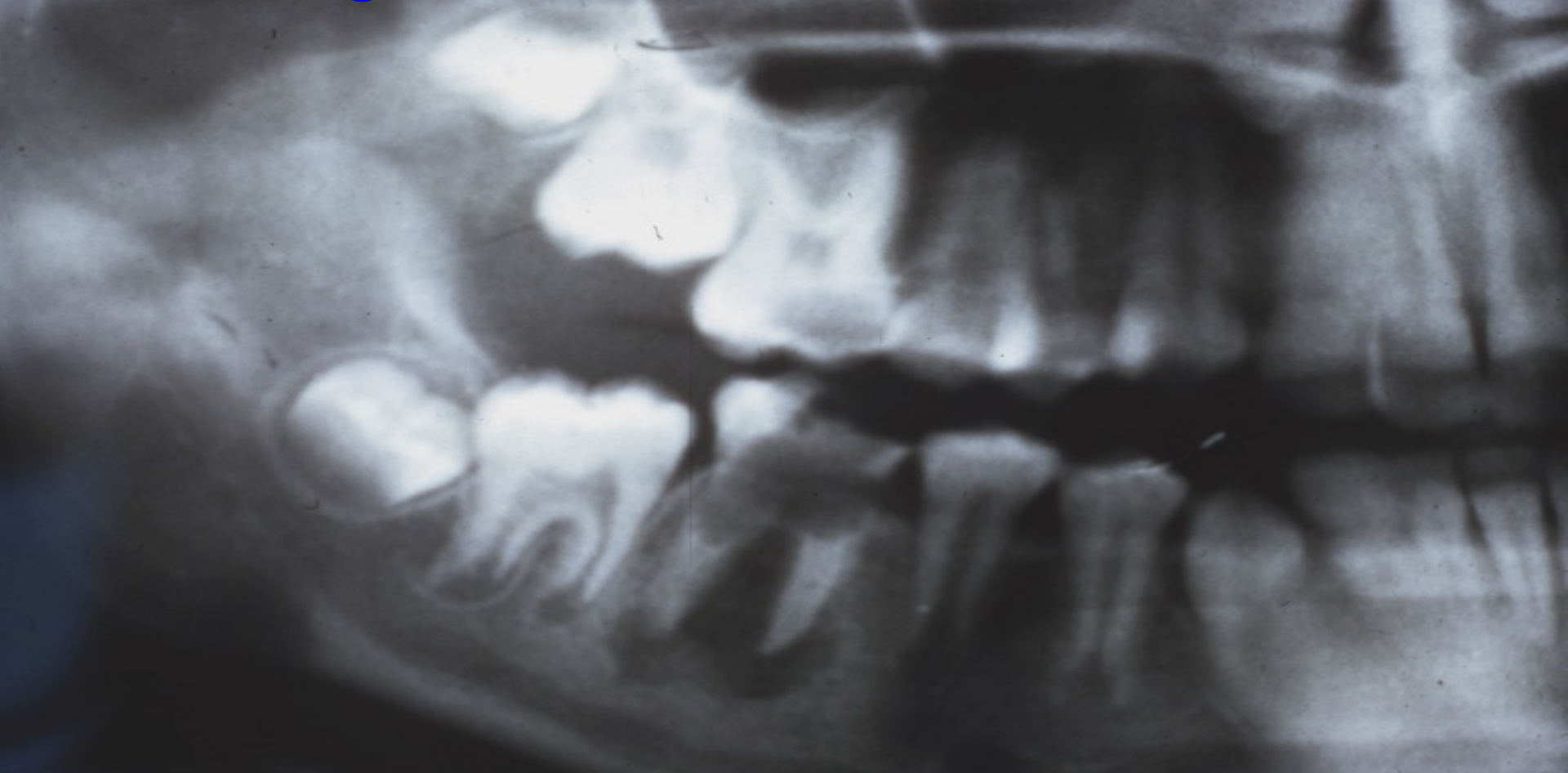Diagram to show how an inferior alveolar nerve block can affect the facial nerve if the local anesthetic is given too far posterior and the needle does not contact bone: (a) normal, (b) injection into parotid gland where facial nerve can be affected.



# *Anatomy and facial trauma*

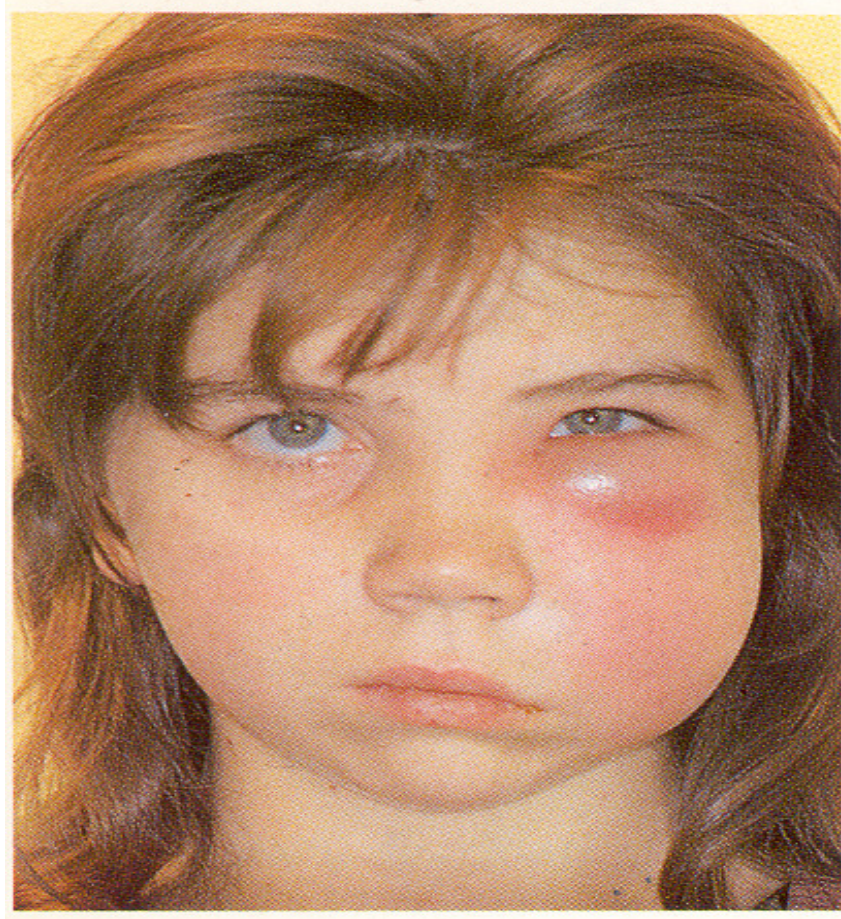
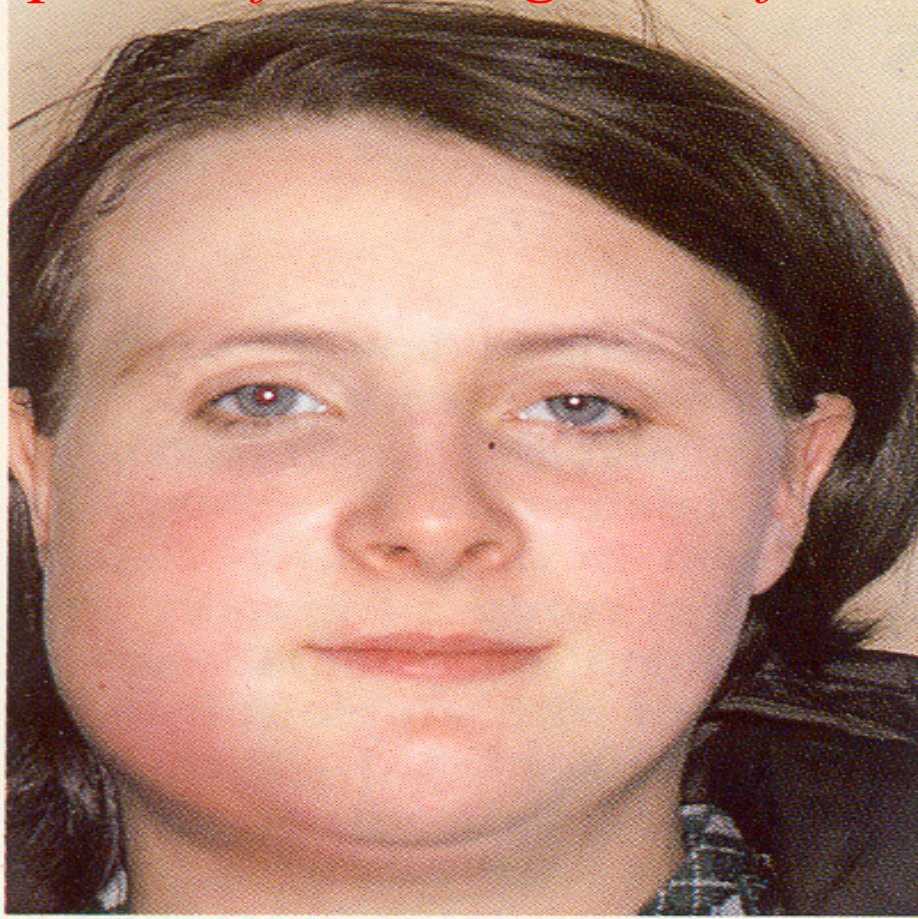
# Odontogenic infection



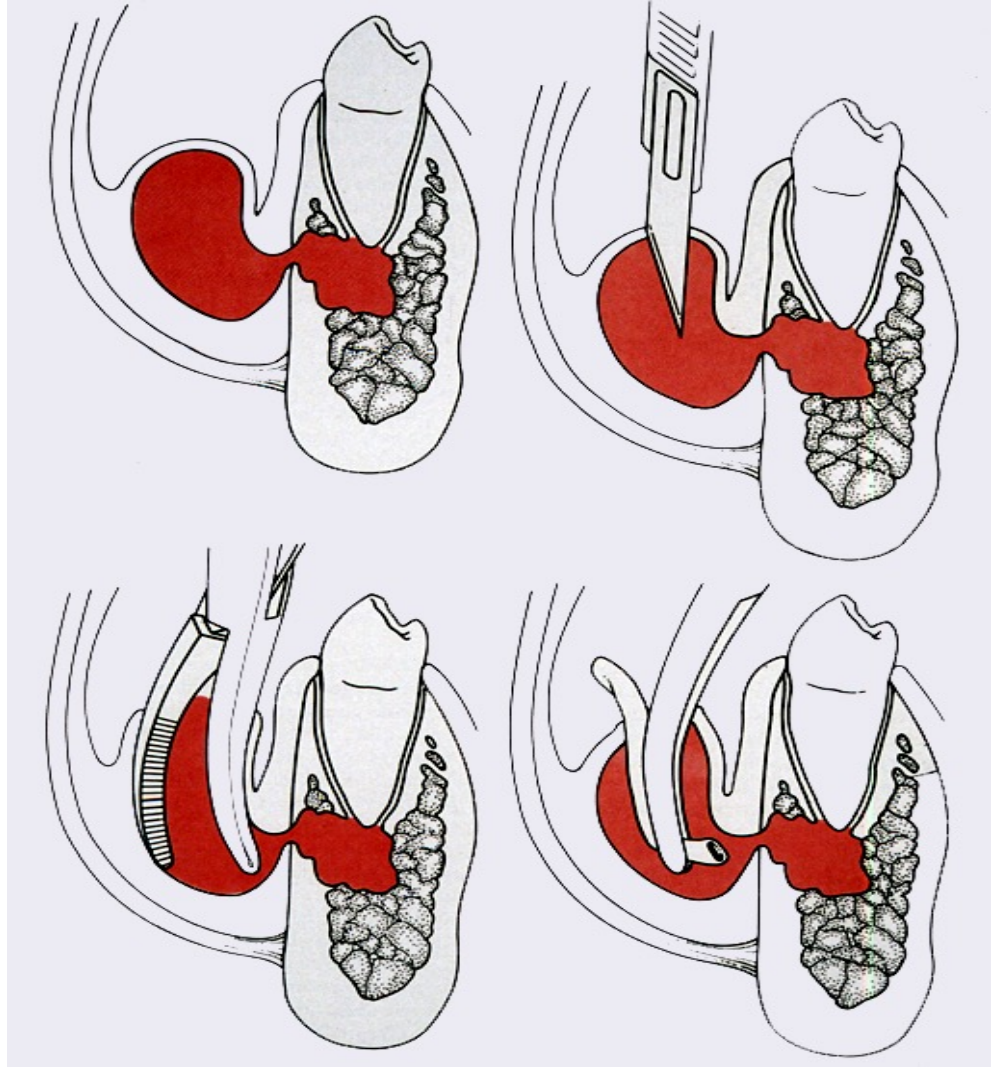


## *Spread of Odontogenic Infection*





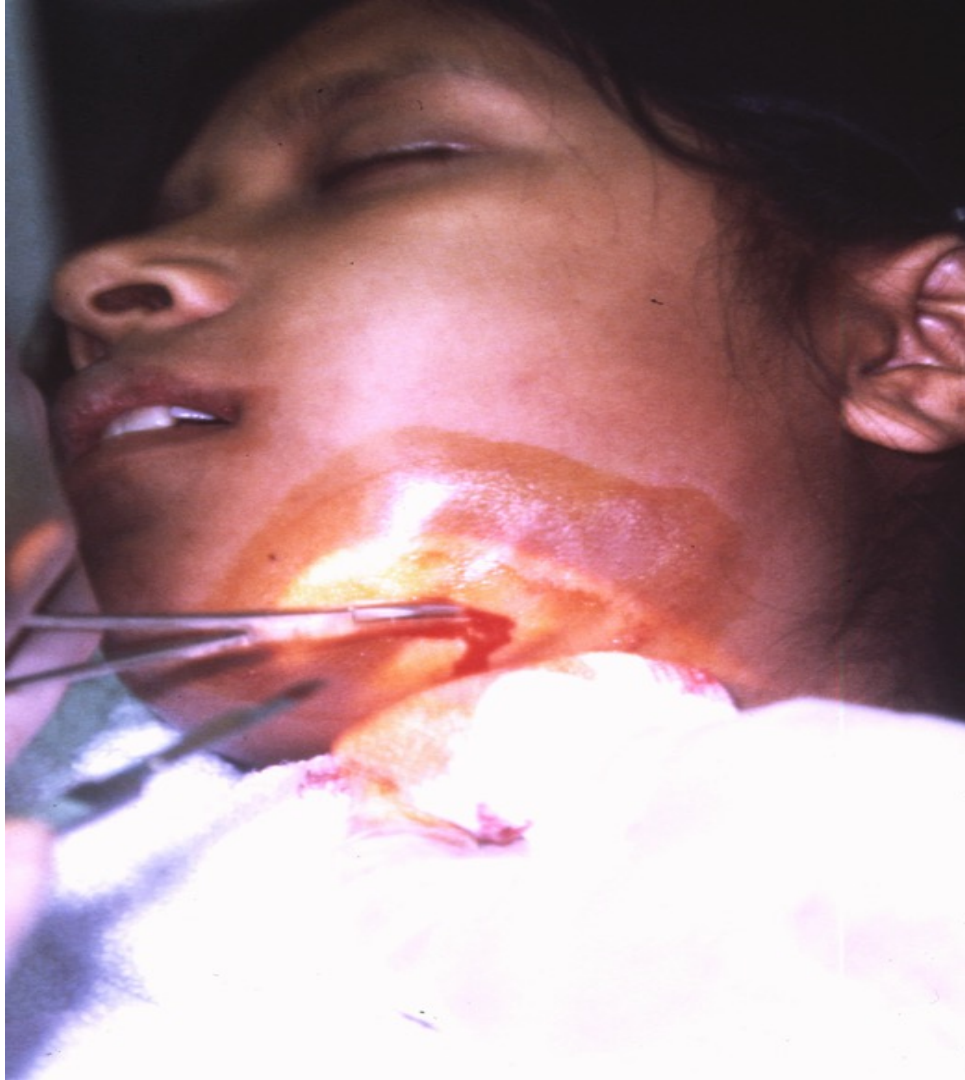# *Intraoral I&D*



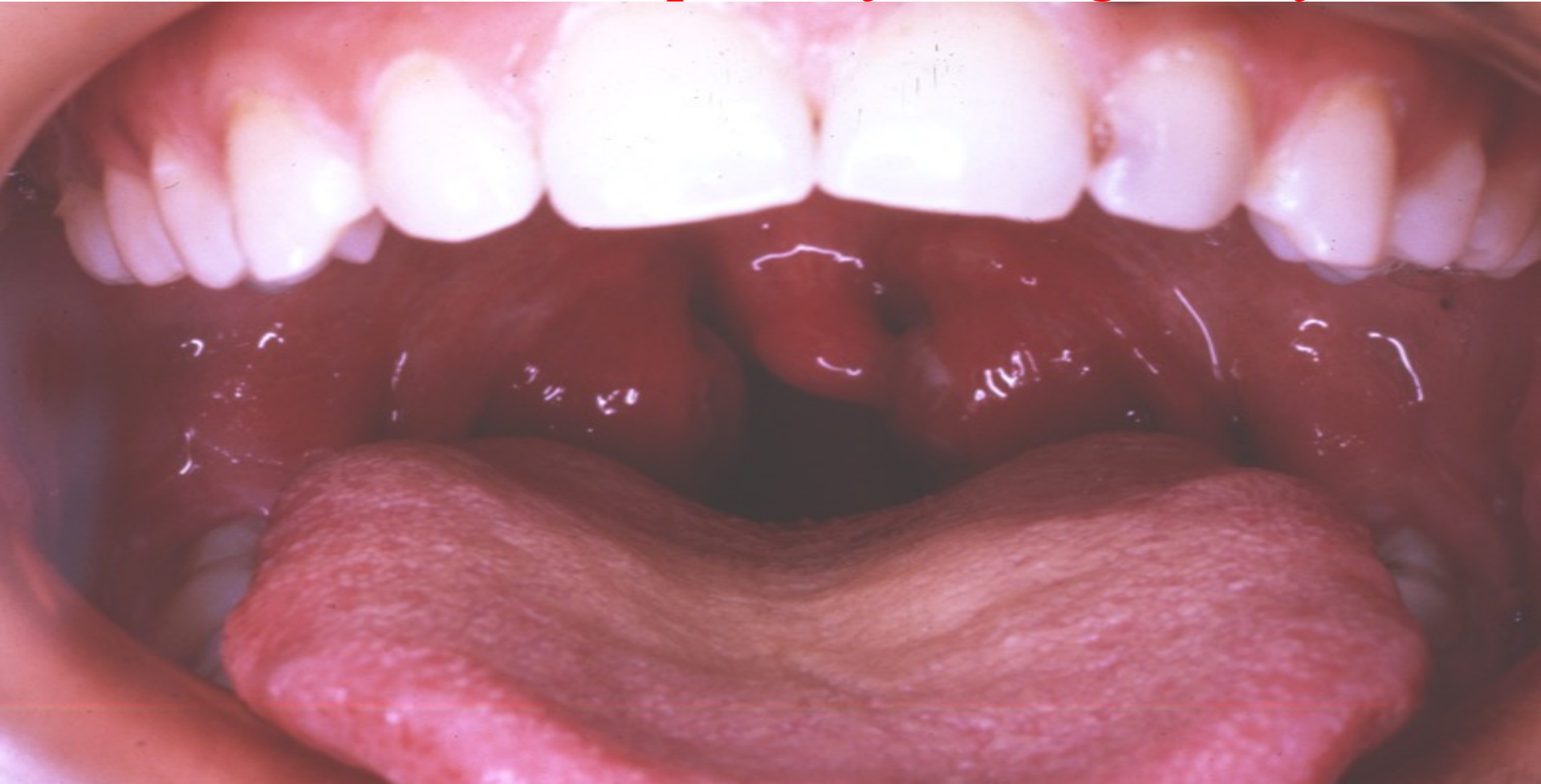

# *Extraoral I&D*

*Potential  
damage to  
the facial  
nerve  
(mandibular  
branch)*

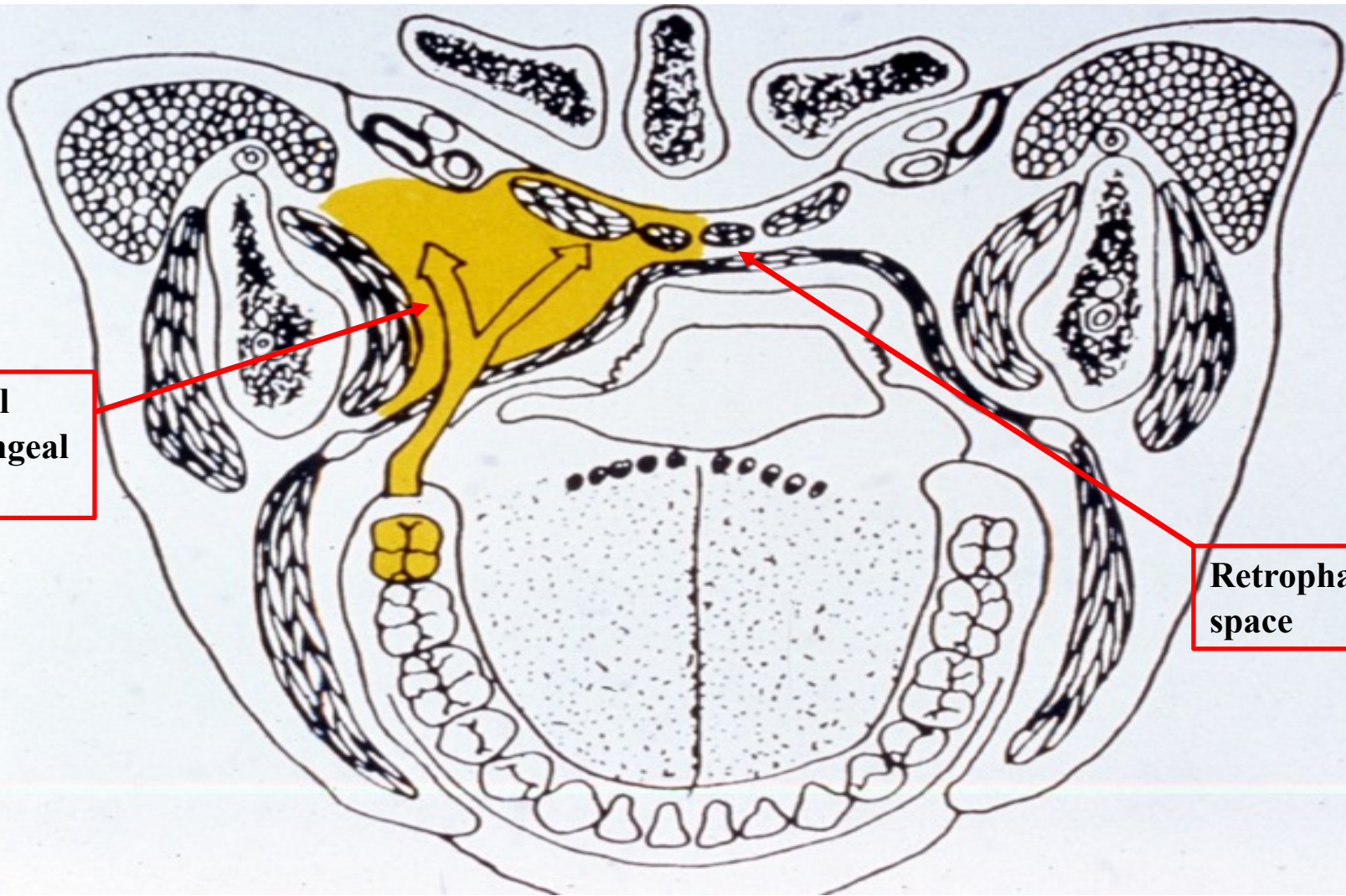


# *Pericoronitis and the spread of odontogenic infection*

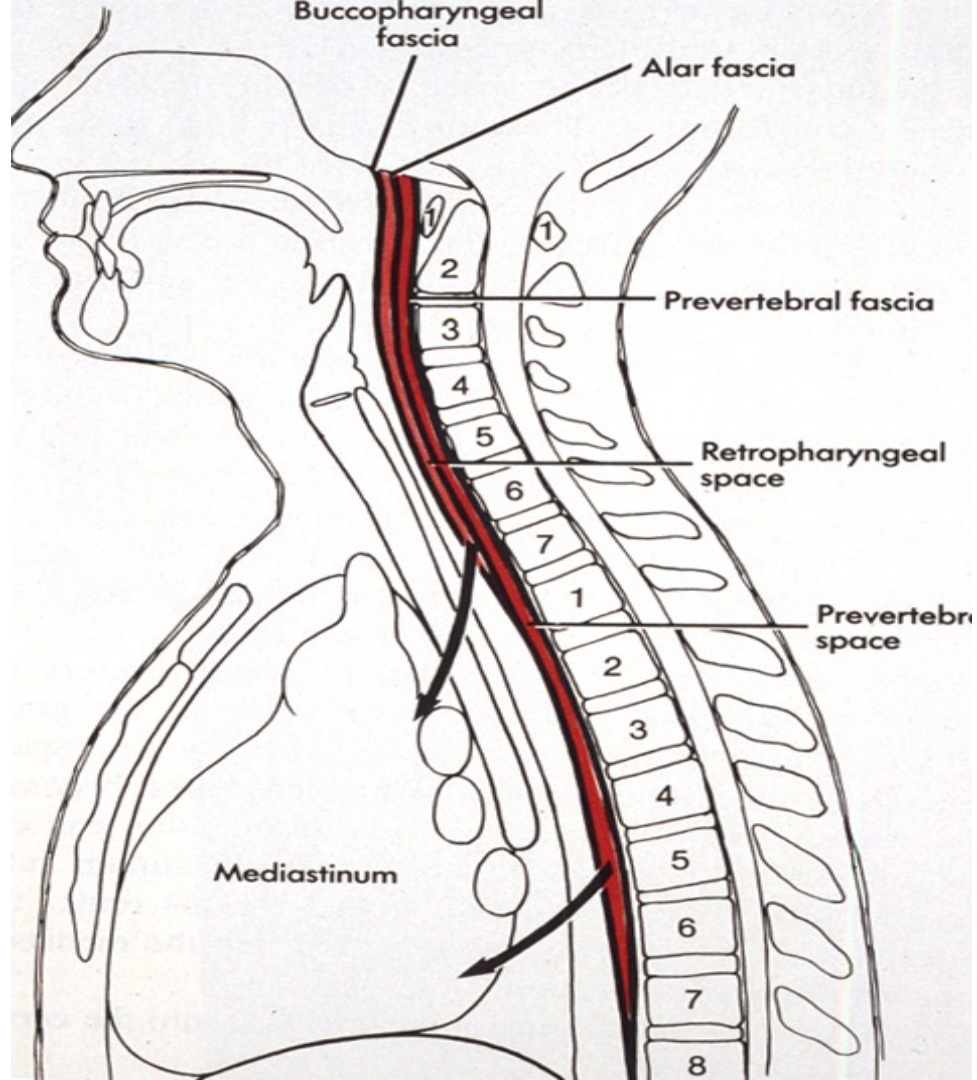


**Lateral  
pharyngeal  
space**

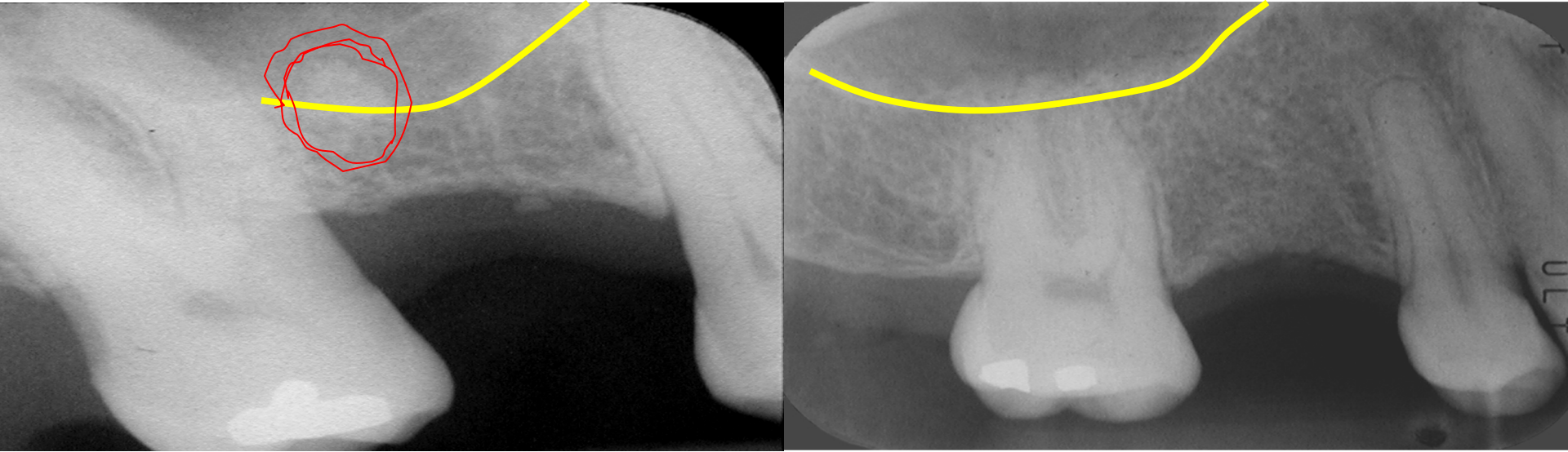
**Retropharyngeal  
space**



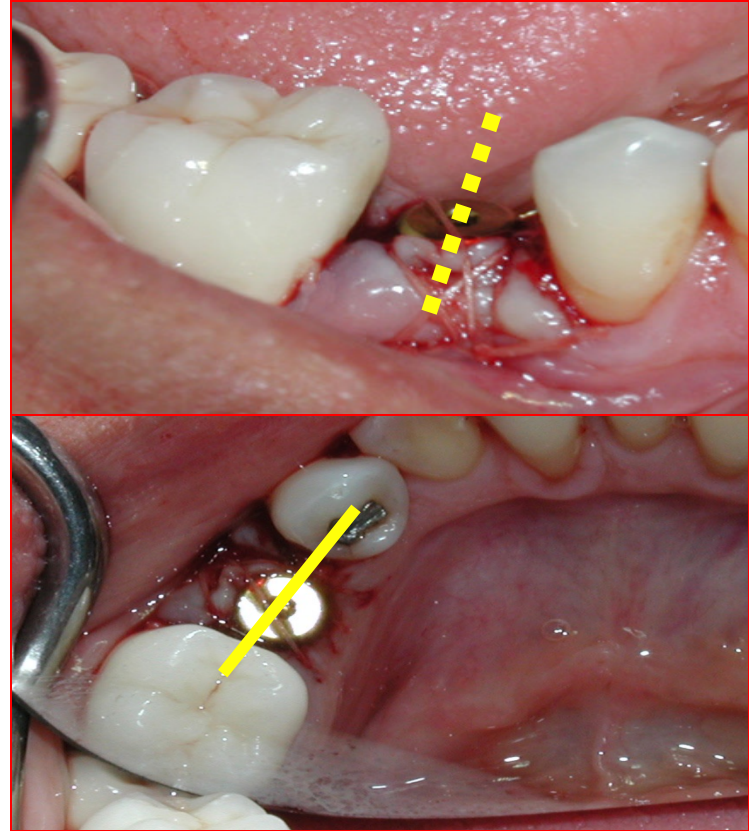
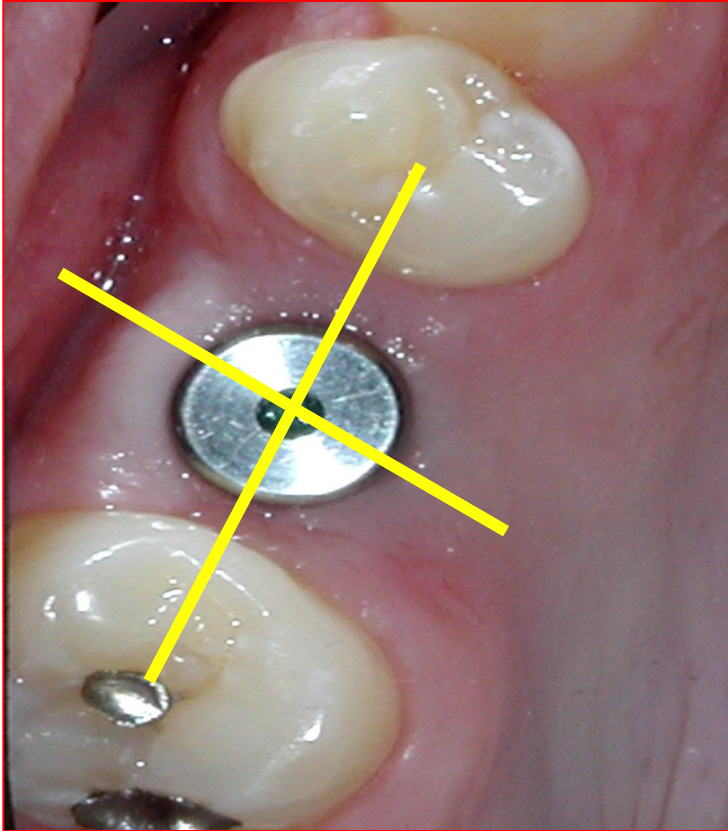




# Maxillary sinus and dental implants



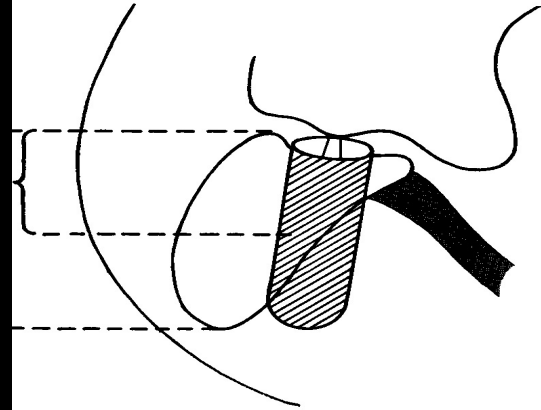
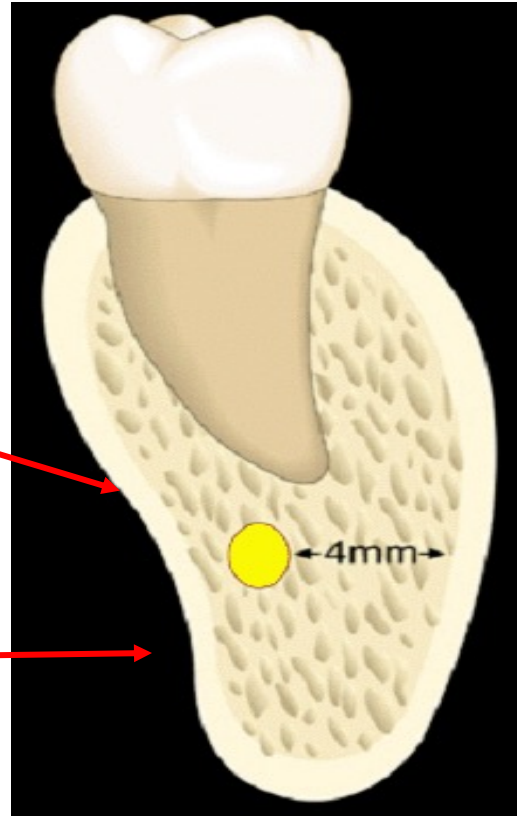
# Alignment of posterior implants



# Anatomy of the Posterior Mandible

Mylohyoid shelf

Submandibular  
fossa



# Neck Anatomy

## Learning objectives

1. Learn the anatomy of the neck, anterior & posterior triangles, cervical fascia and the associated clinical considerations
2. Identify and describe all branches of the external carotid artery, identify internal and common carotid arteries. Know the function and innervation of the carotid body and the carotid sinus.
3. Describe all venous structures and nerves in the neck.
4. Describe all muscles in the anterior and posterior triangles of the neck, know their innervations and functions.
5. Identify submandibular and sublingual glands, describe nerve innervations to these salivary glands
6. Learn the lymphatic drainage of the head and neck. Describe the spread of infection in the head and neck region.
7. Describe arteries, veins, nerves and muscles at the root of the neck.



# **Boundaries of the Neck**

- **Anterior Aspect:**

**Superior: Inferior border of the mandible**

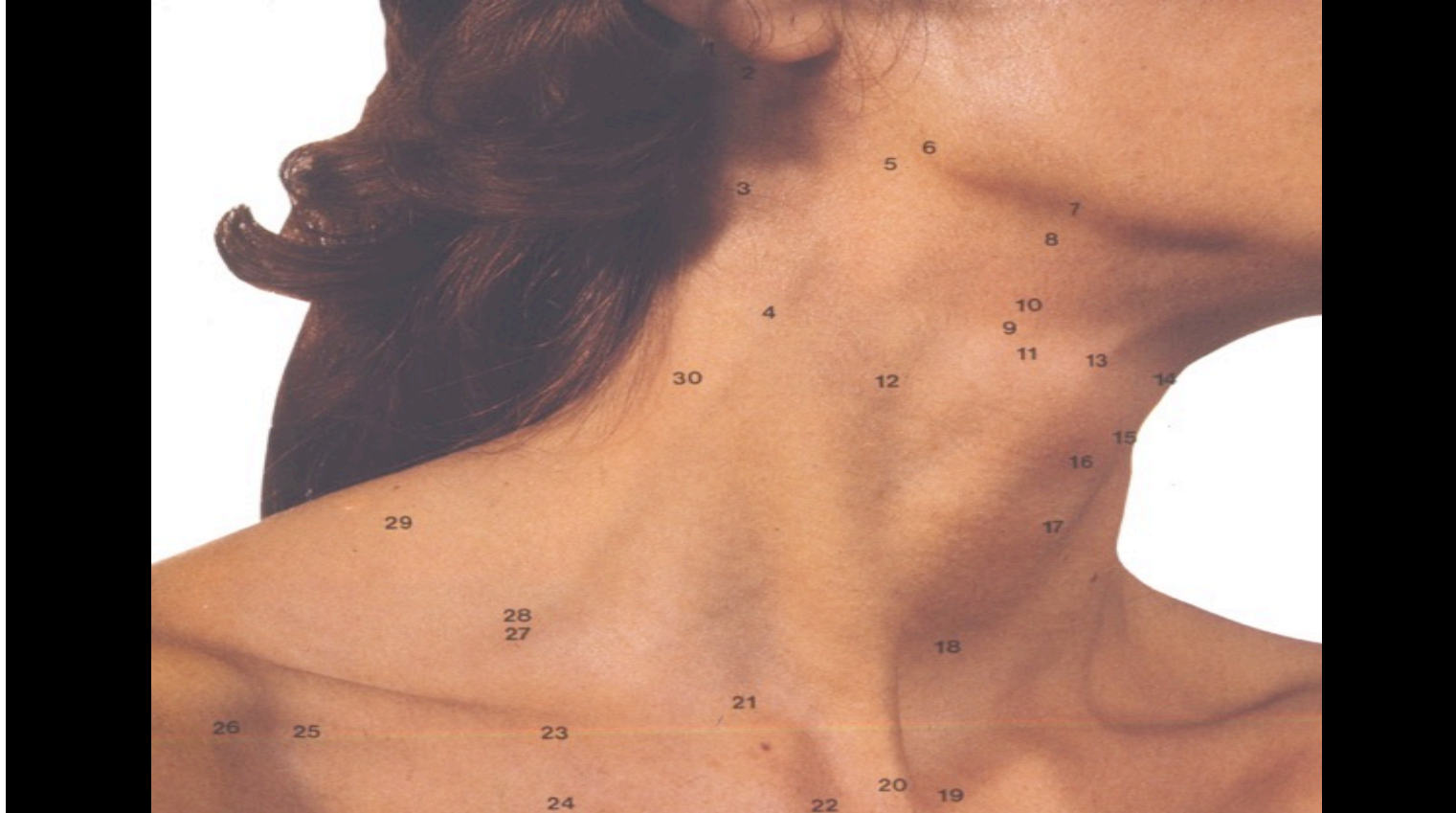
**Inferior: Superior surface of the  
manubrium and clavicle**

- **Posterior Aspect:**

**Superior: Superior nuchal line**

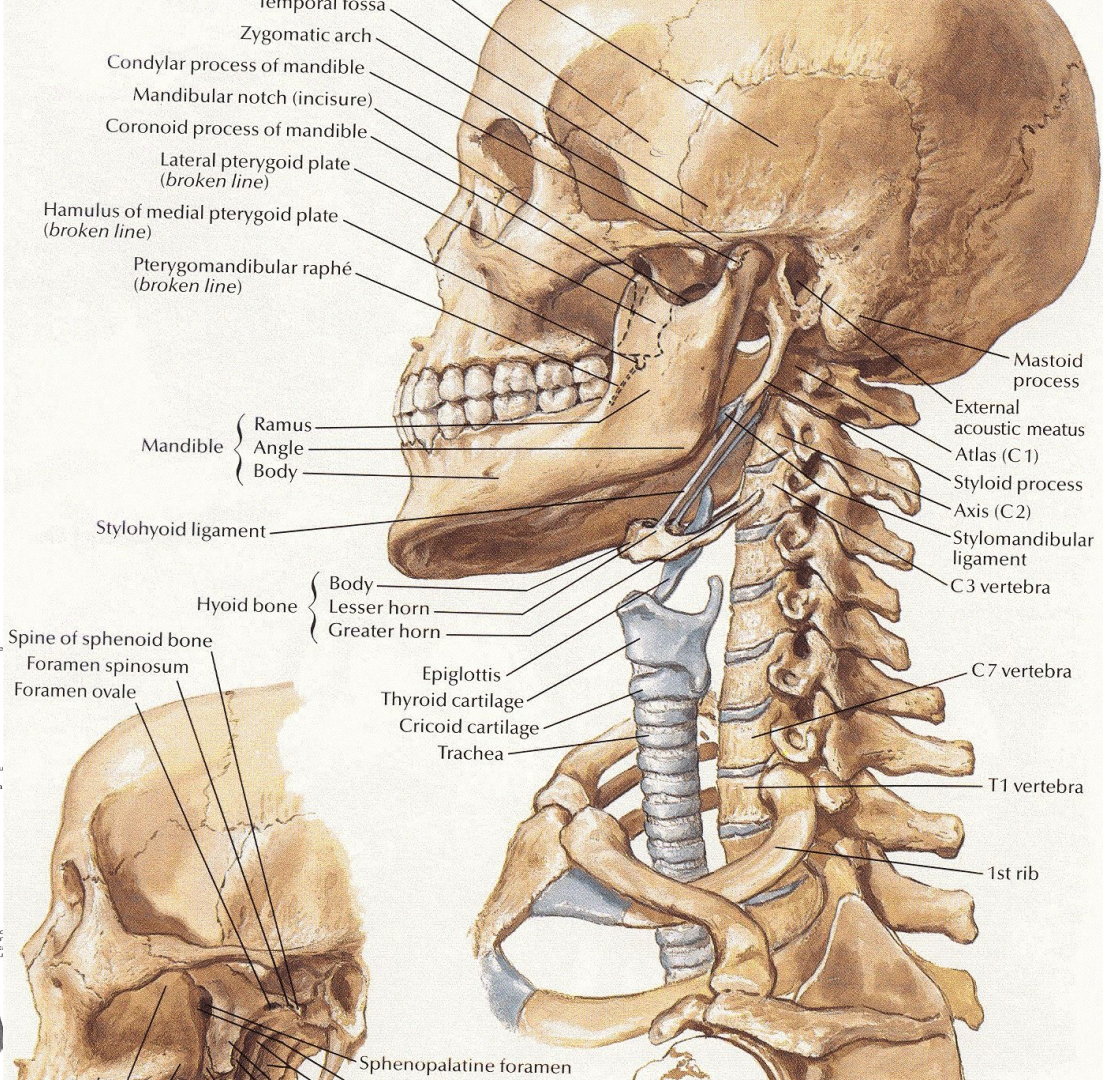
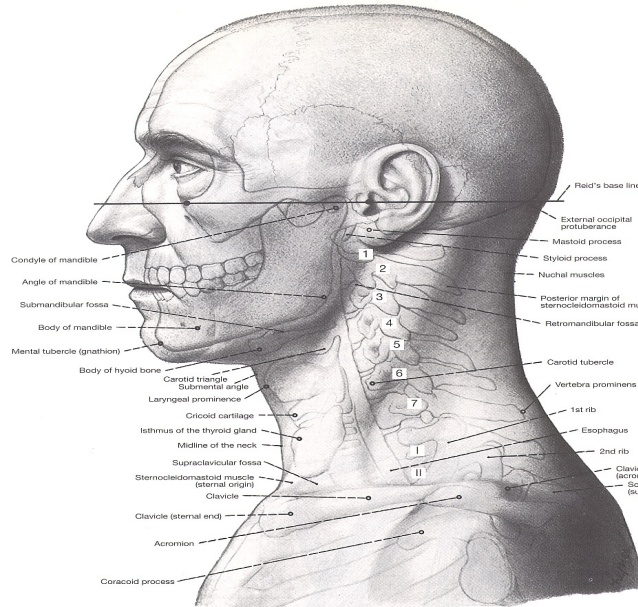
**Inferior: Horizontal line between C7 and  
T1**

# Boundaries of the Neck



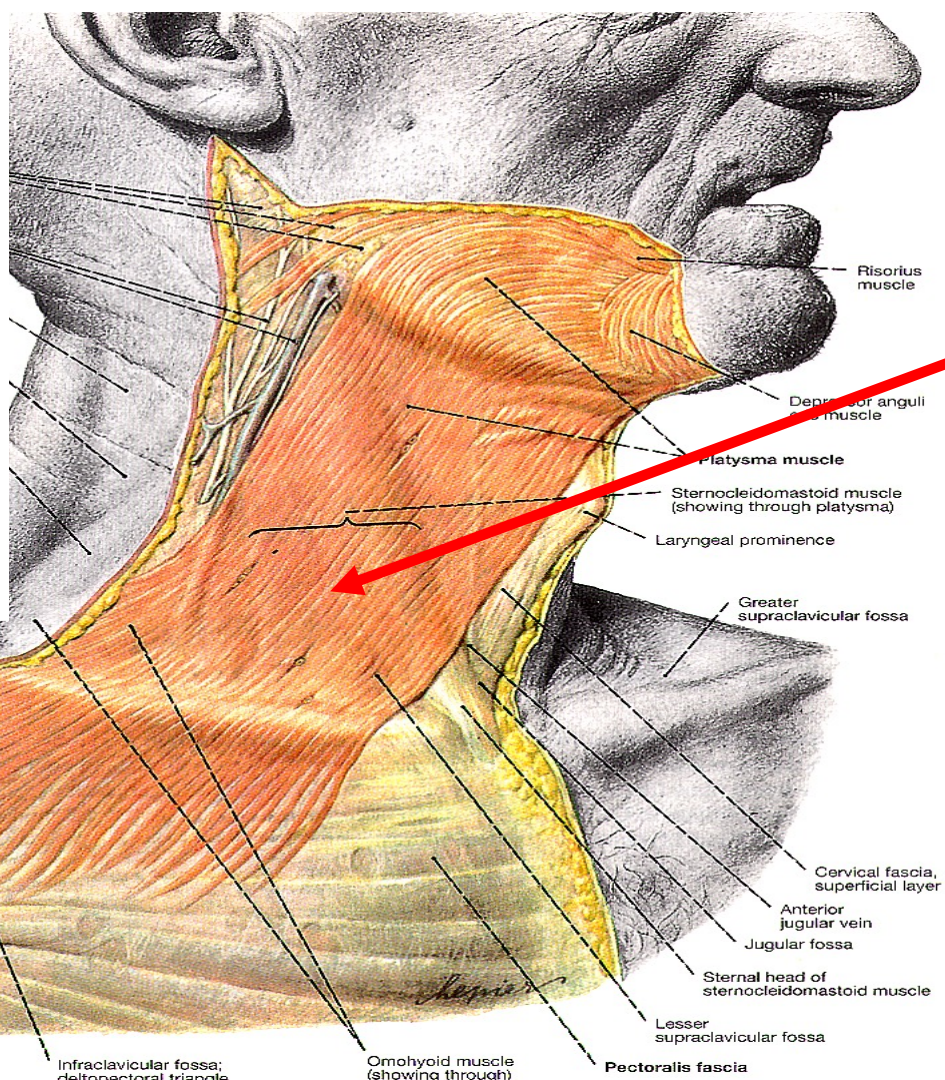
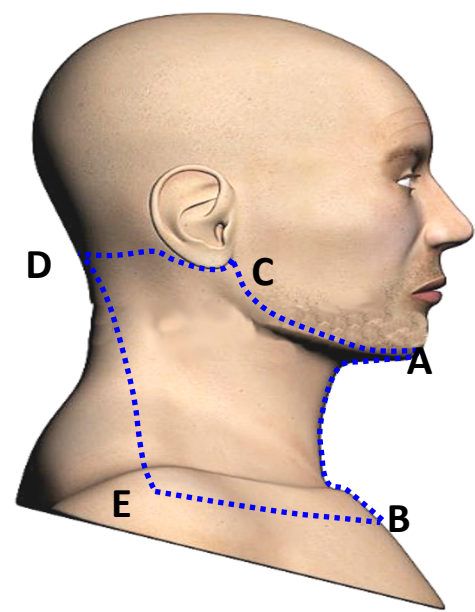


# Neck anatomy





# Platysma muscle



# Platysma

- **Covers mainly anterior aspect of the neck.**
- **Origin: deltoid and pectoralis fasciae.**
- **Insertion: inferior border of mandible and skin as well as hypodermis in this region.**
- **Function: assist depression the lower lip and corner of mouth.**
- **Innervation: cervical br. of facial N. (VII).**

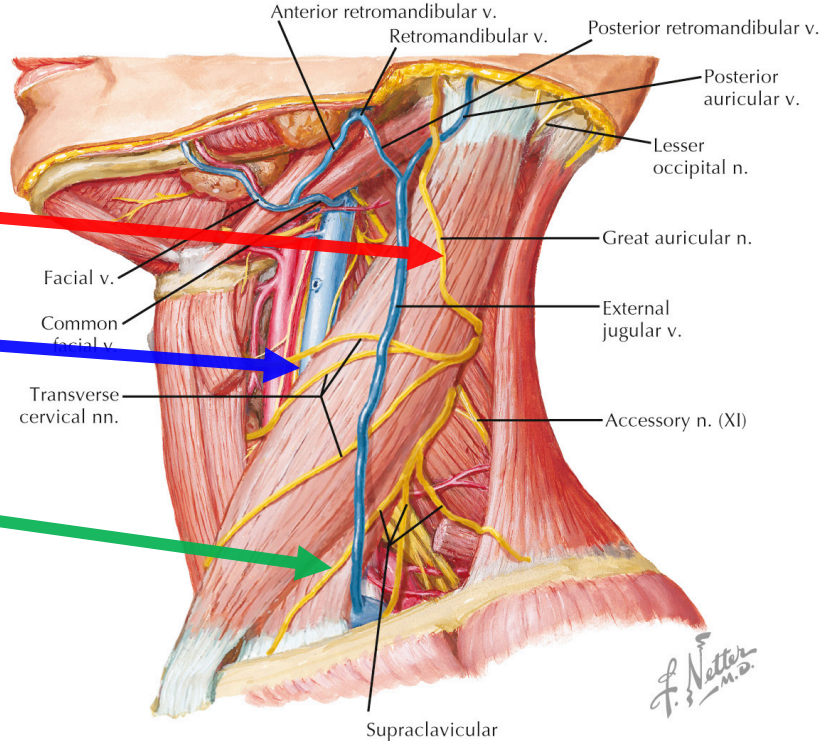


# Sensory Innervation of Neck

- C1, C2, C3, and most of C4 form the cervical plexus (**Somatosensory**)

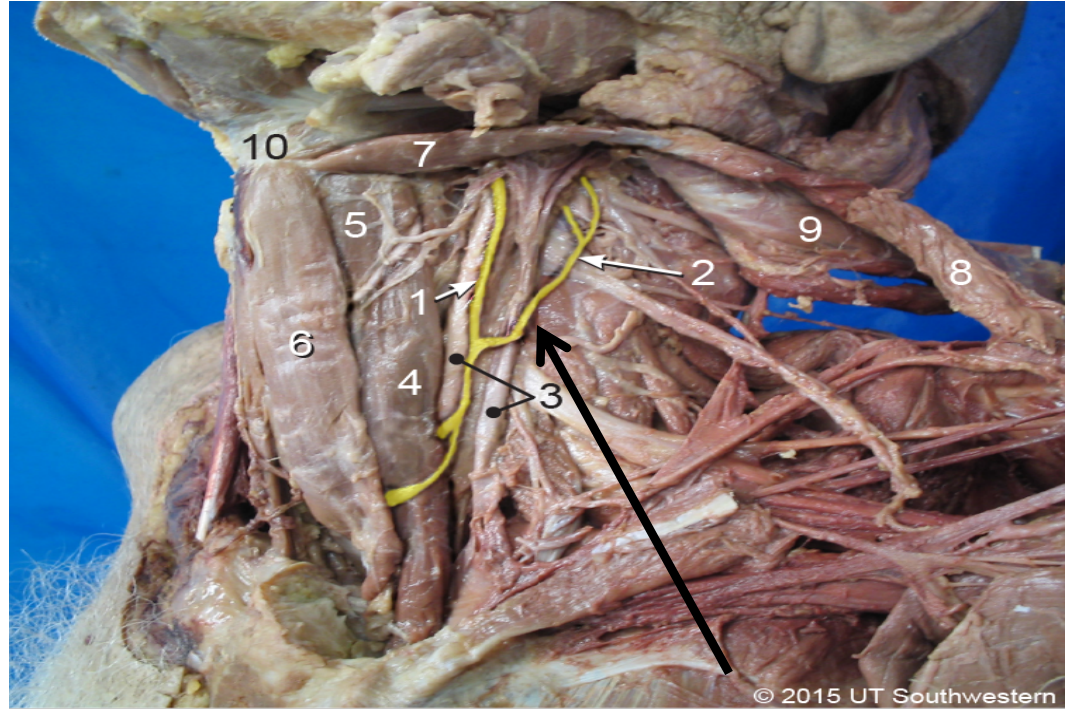
- Front of neck:

1. Great auricular N. (C2 & C3)
2. Transverse cervical N. (C2 & C3)
3. Supraclavicular N. (C2 & C4)
  - a. Anterior (medial)
  - b. Middle (intermediate)
  - c. Posterior (lateral)



# Ansa Cervicalis

- Two roots (formed by C1, C2, and C3)
  - Somatomotor nerve
  - Superior root (travels with CN XII)
  - Inferior root (from cervical region)



*Function: Motor innervation of infrahyoid muscles*

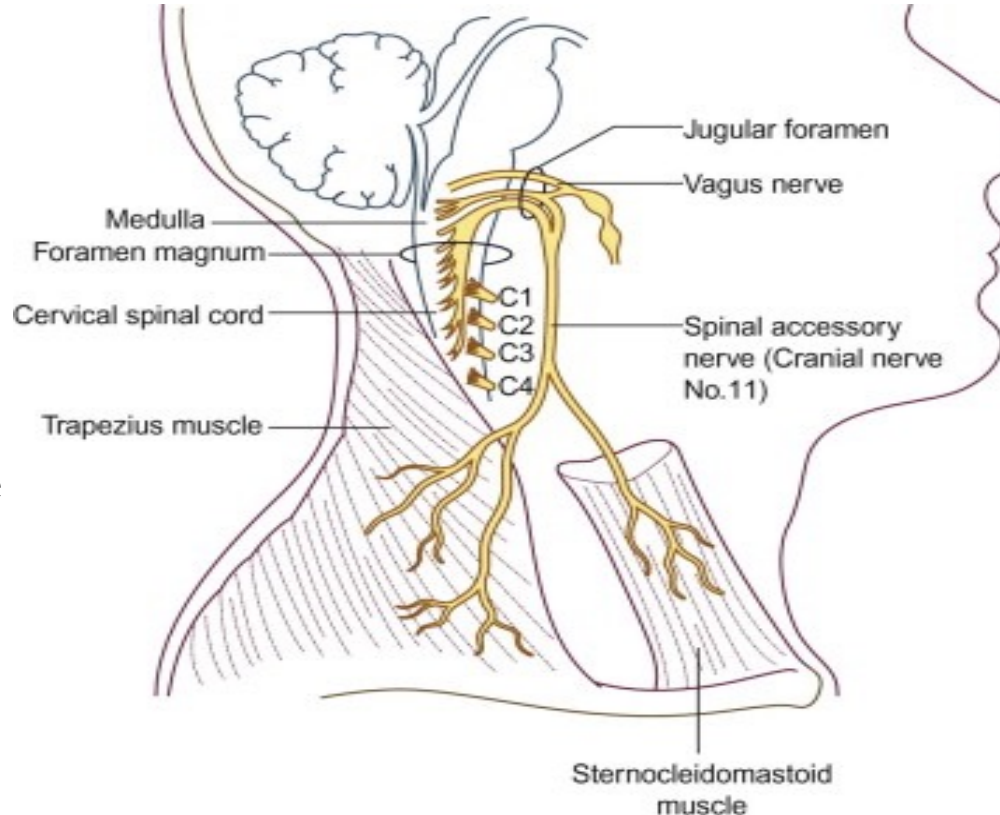
# Accessory Nerve (CN XI)

**Two components of fibers**

- 1. Cranial root**
- 2. Spinal root**

**Function: motor innervation of**

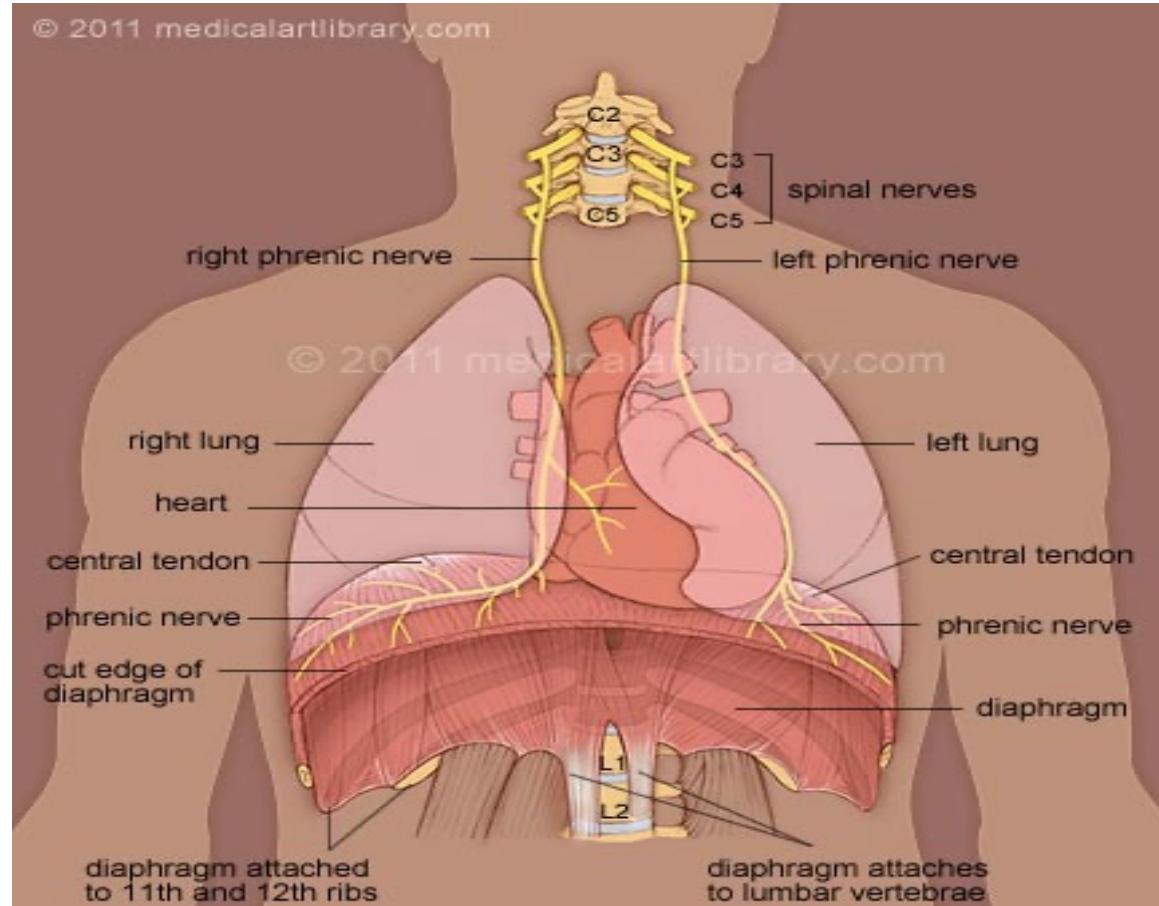
- 1. Sternocleidomastoid muscle (SCM)**
- 2. Trapezius muscle**





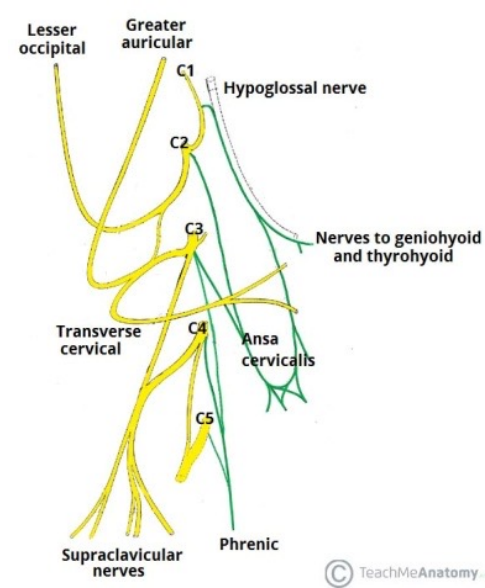
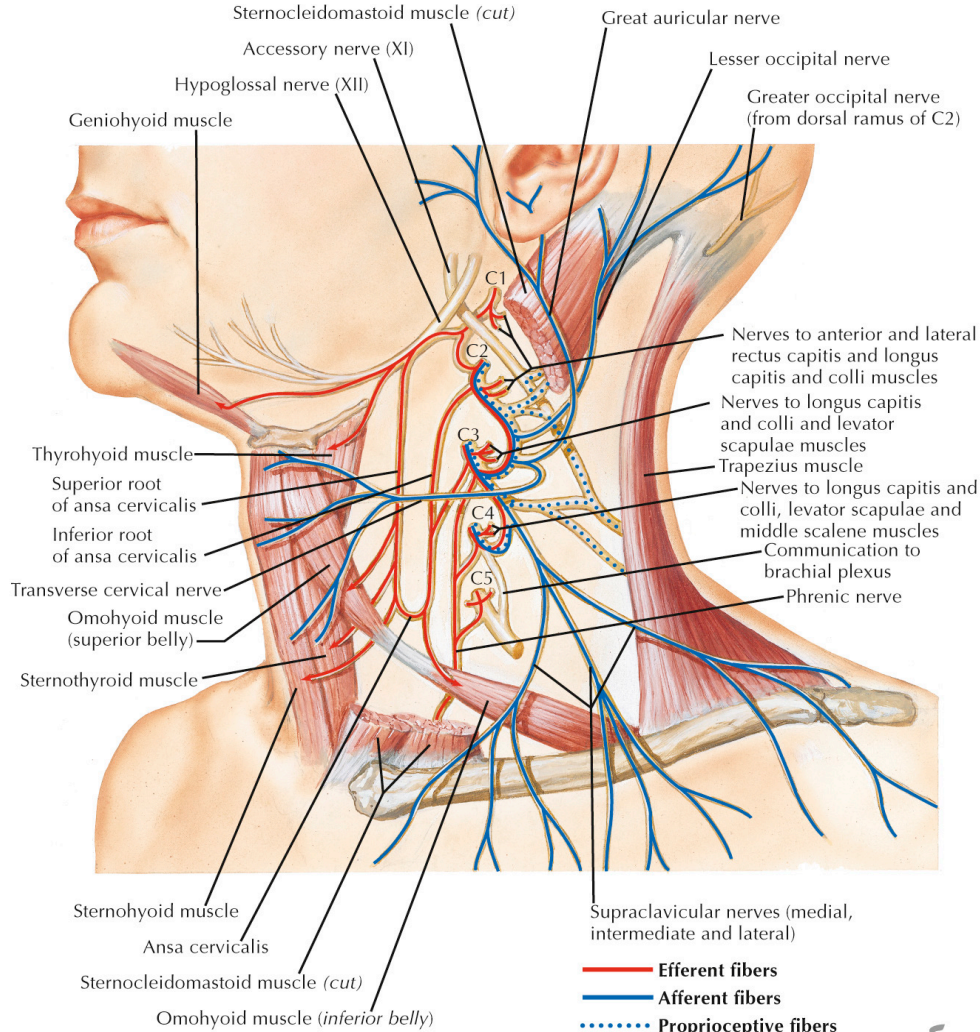
# Phrenic Nerve (C3, C4, and C5)

- Motor: Diaphragm
- Sensory: Mediastinal pleura and pericardium of the heart



# Cervical Plexus

1. Motor
2. Sensory



Cervical sympathetic trunk, vagus nerve, and glossopharyngeal nerve have been cut. The dashes line indicates a segment of the epineurium of the hypoglossal nerve.

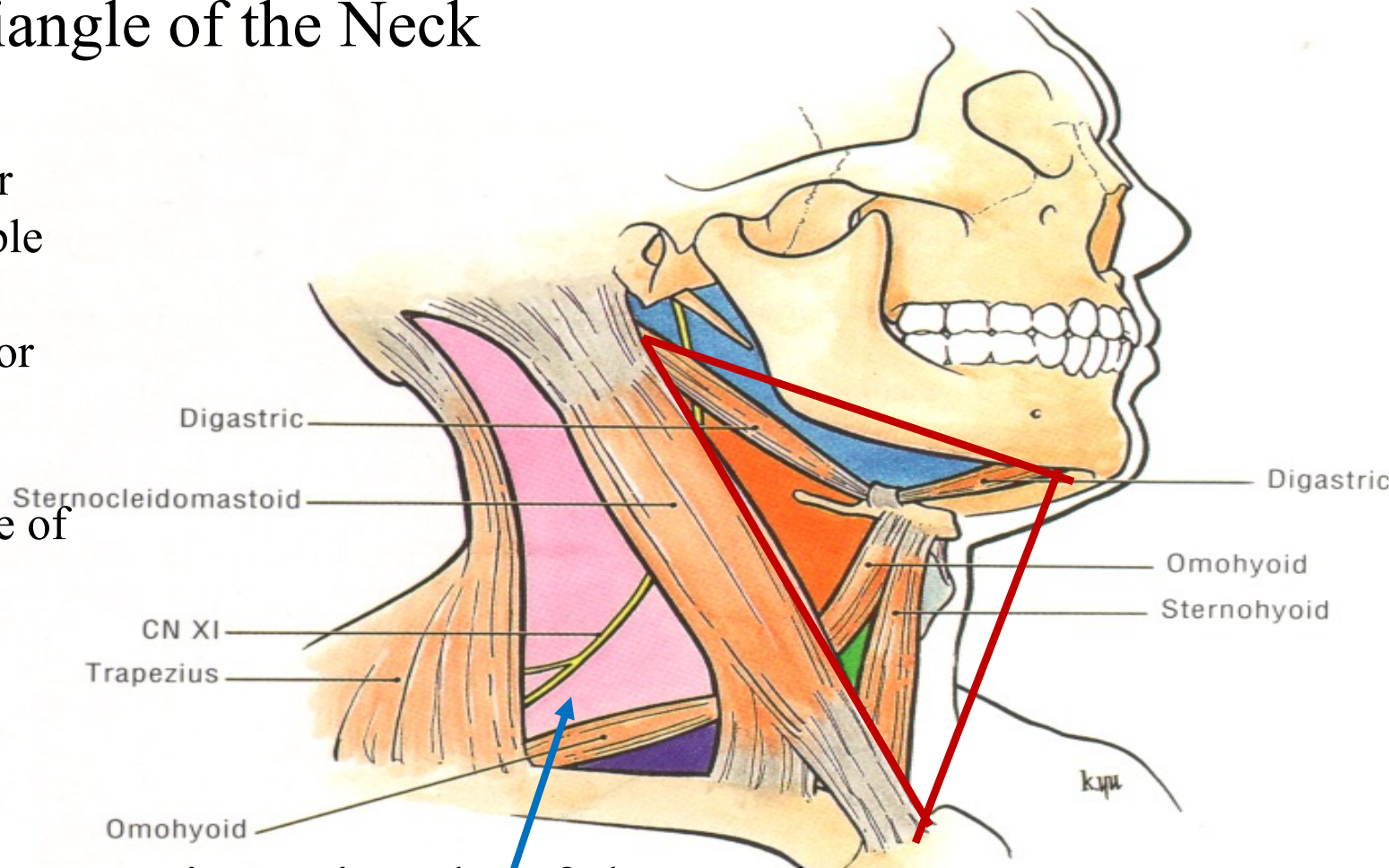
# Anterior Triangle of the Neck

Boundaries:

**Superior:** Inferior border of mandible

**Posterior:** Anterior border of SCM

**Anterior:** Midline of the neck

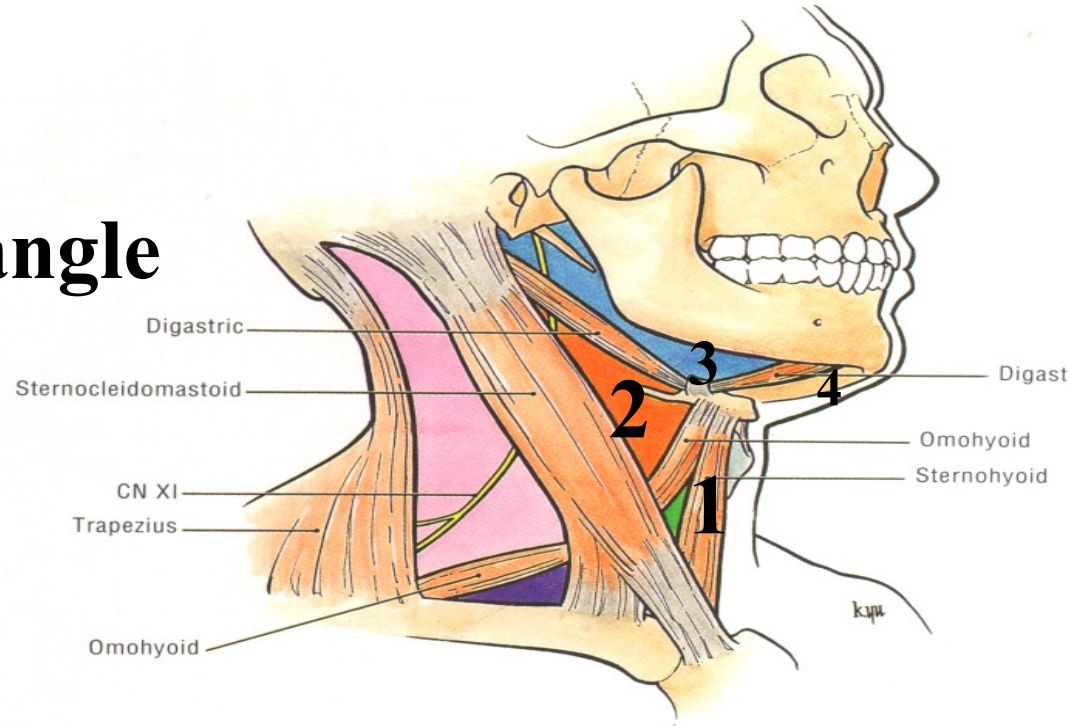


## Posterior Triangle of the Neck



# Subdivisions of anterior triangle of the neck

1. Muscular Triangle
2. Carotid Triangle
3. Submandibular Triangle
4. Submental Triangle





# Subdivisions of anterior triangle of the neck

## 1. Muscular Triangle

Boundaries:

**Superior:** Superior belly of omohyoid

**Inferior:** Anterior border of SCM

**Anterior:** Midline

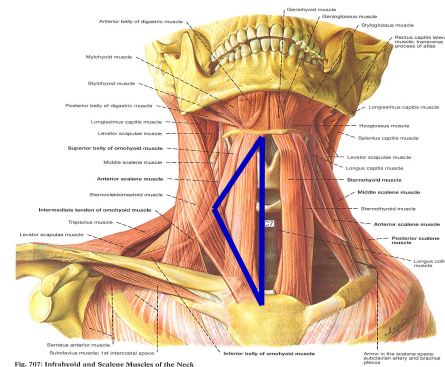
Contents:

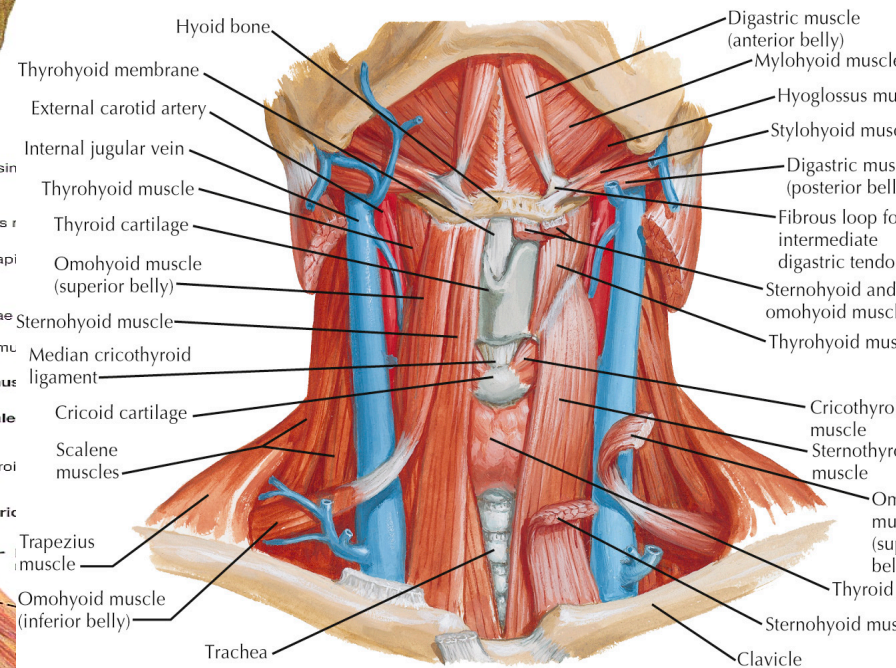
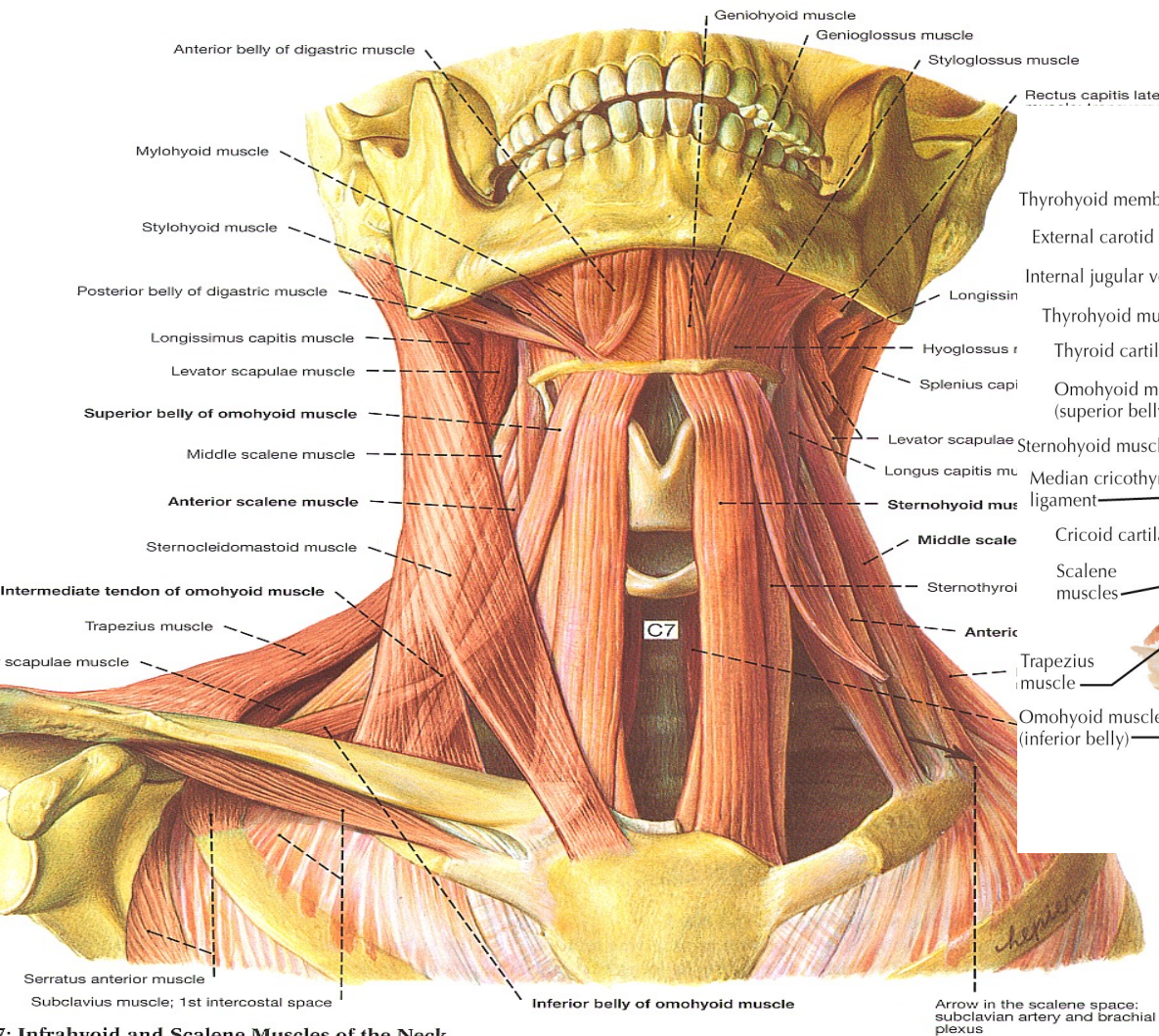
a. sternohyoid (ansa)

b. sternothyroid (ansa)

c. thyrohyoid (C1 via CN XII)

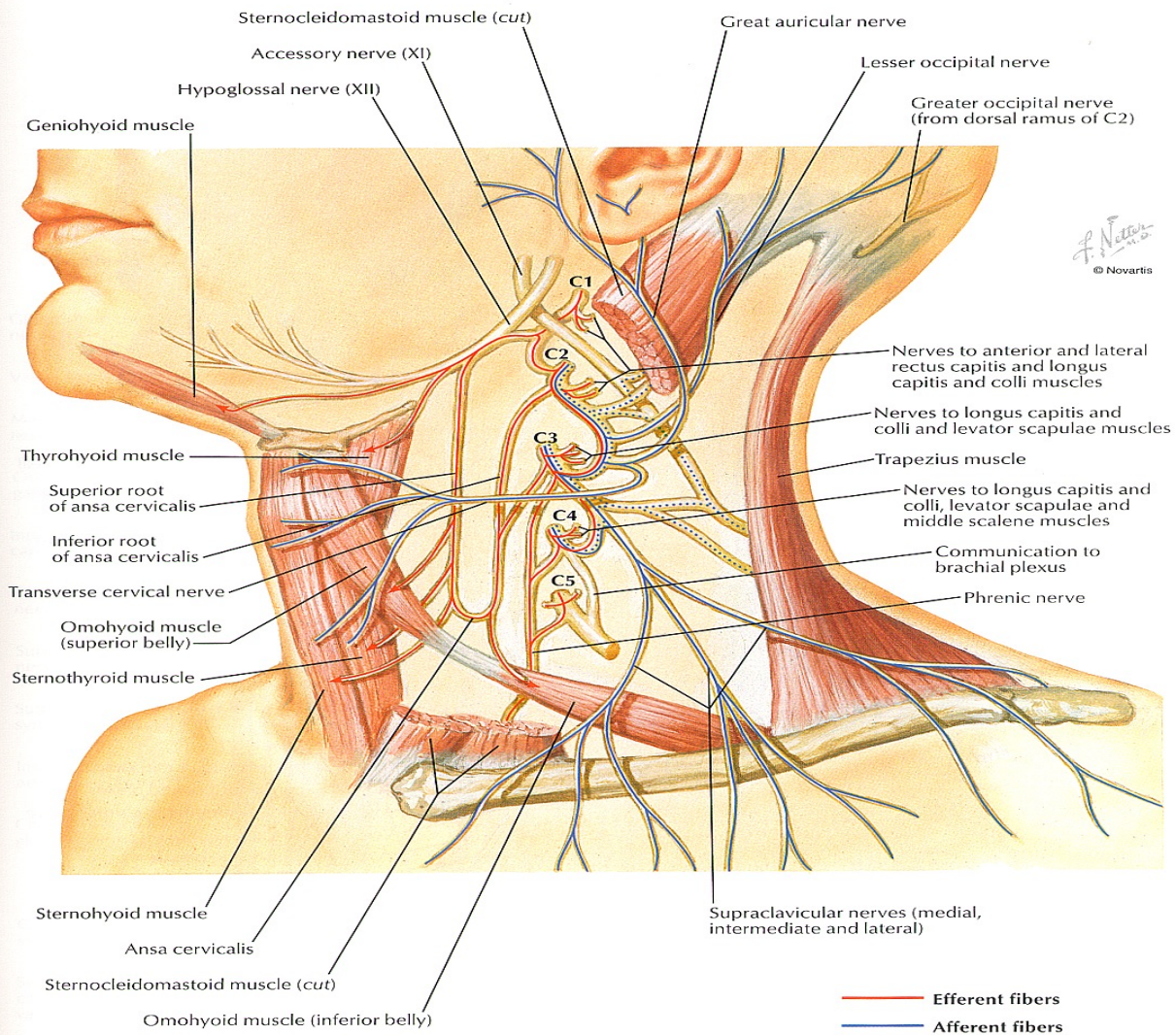
d. omohyoid (ansa)





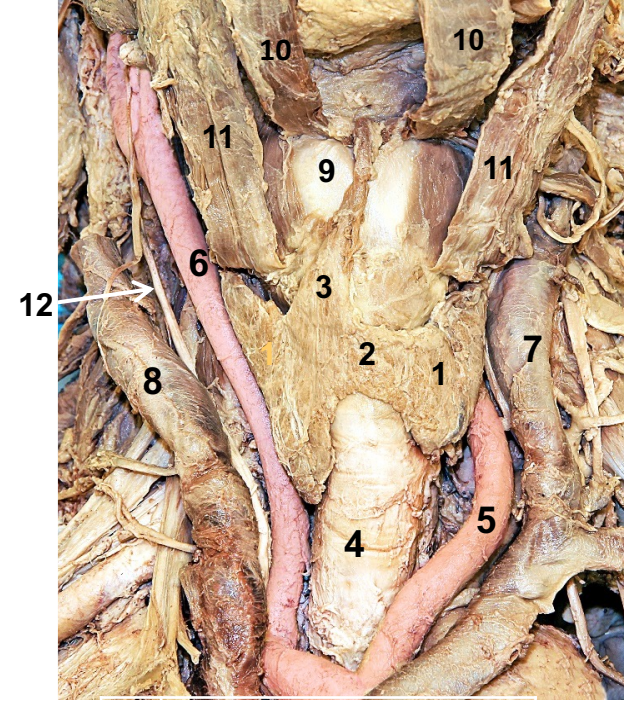
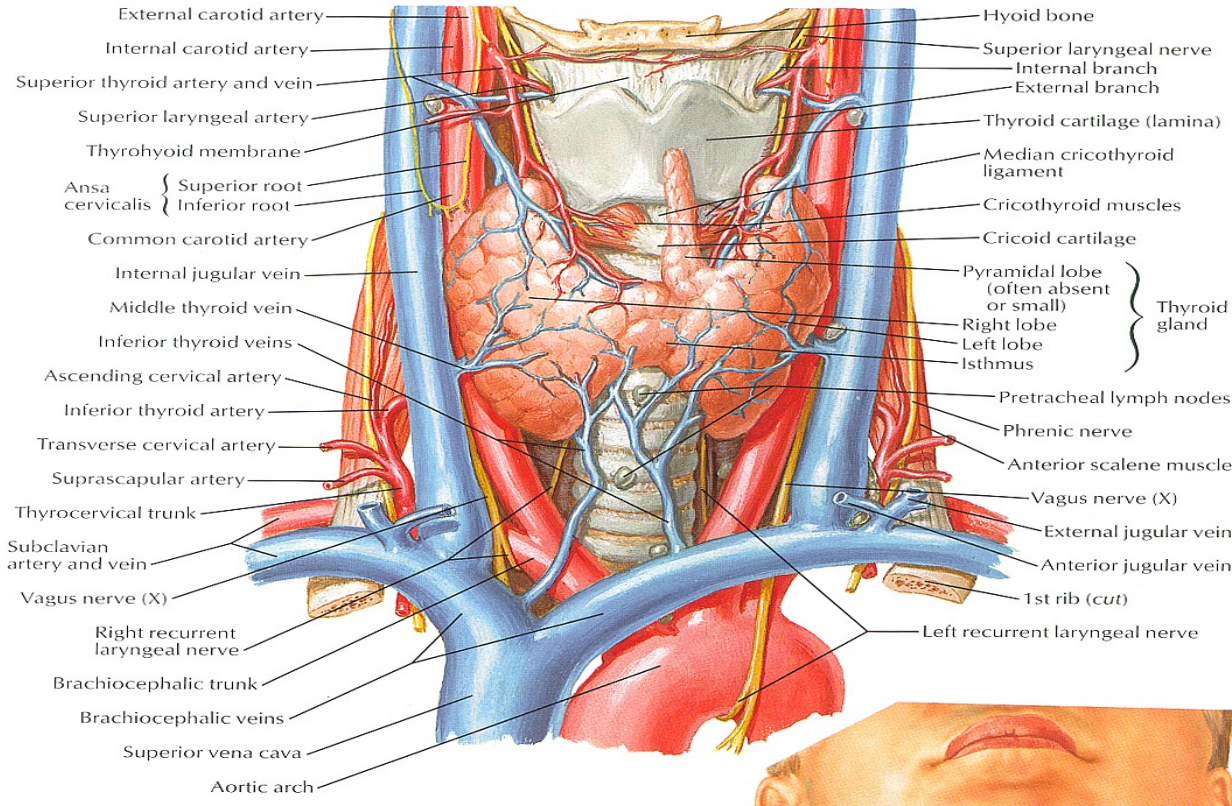


# Innervation to infrahyoid muscles





# Thyroid gland



- 1 Thyroid gland
- 2 Thyroid isthmus
- 3 Pyramidal lobe
- 4 Trachea
- 5 Left common carotid artery
- 6 Right common carotid artery
- 7 Left internal jugular vein
- 8 Right internal jugular vein
- 9 Thyroid cartilage
- 10 Sternohyoid muscles
- 11 Sternothyroid muscles
- 12 Right vagus nerve



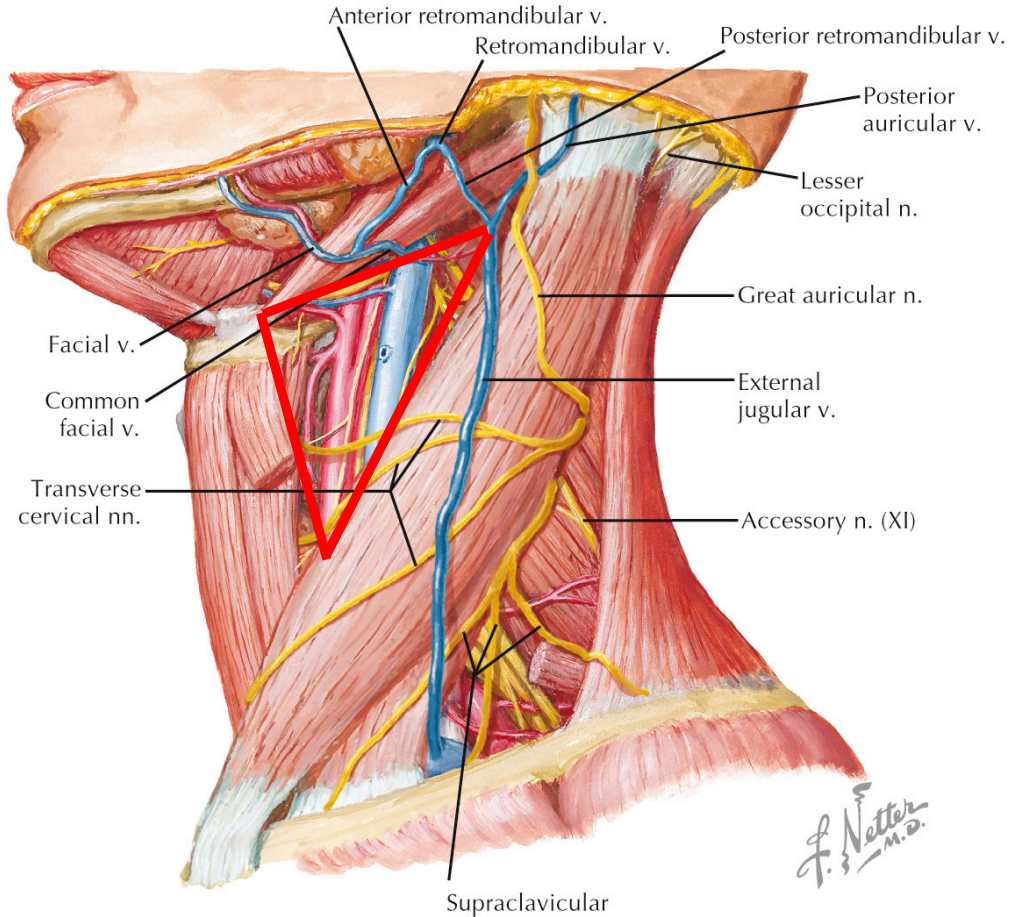
# 2. Carotid Triangle

**Boundaries:**

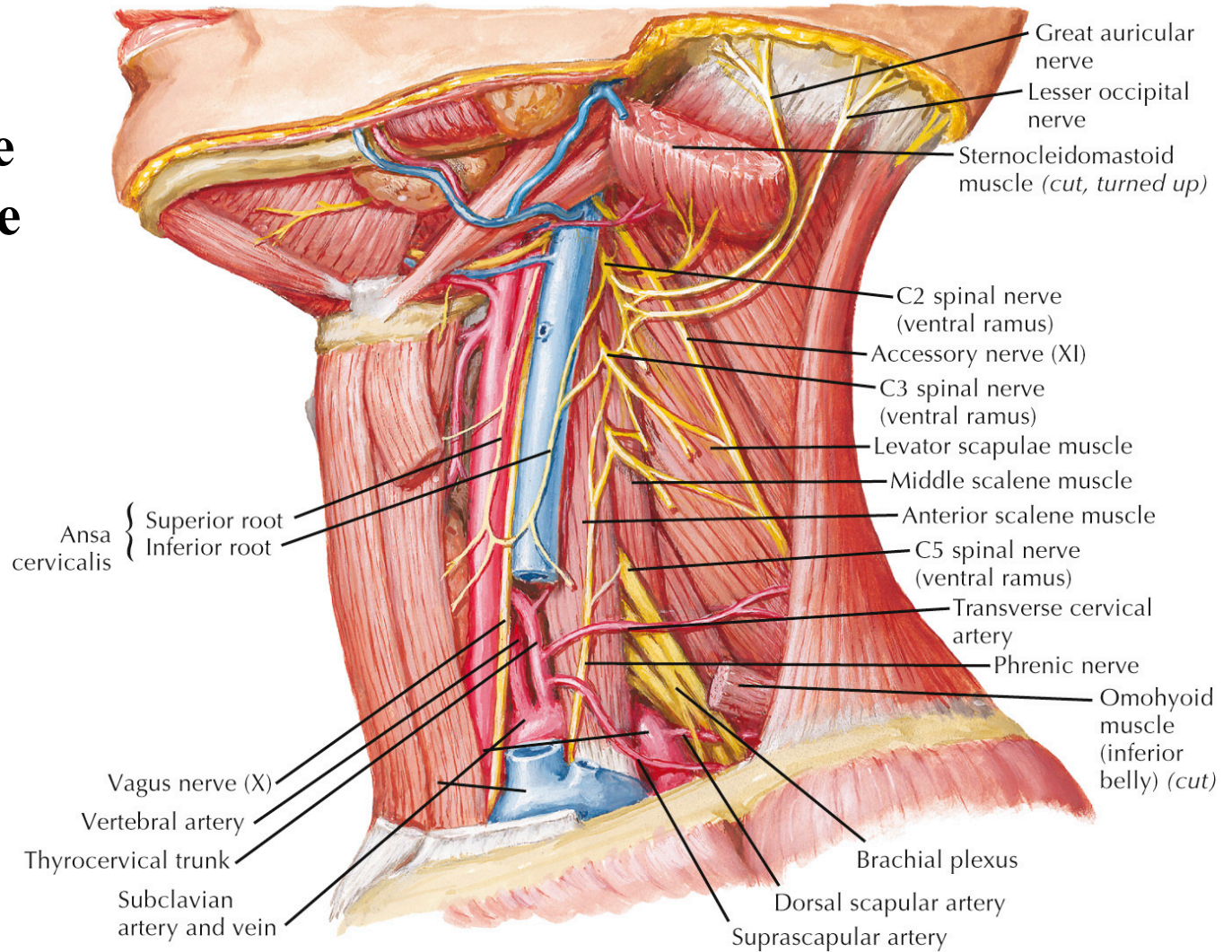
**Superior:** Posterior belly of digastric muscle

**Inferior:** Superior belly of omohyoid

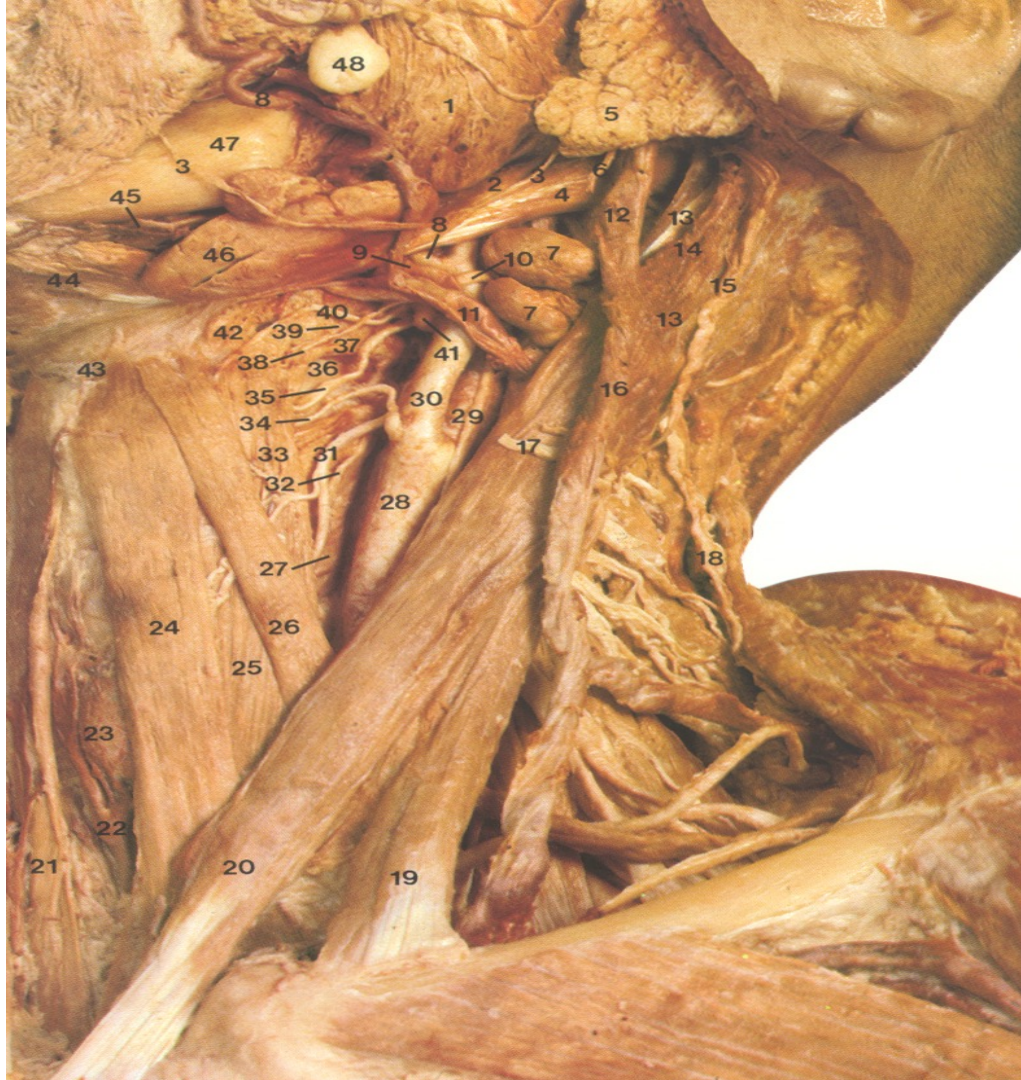**Posterior:** Anterior border of SCM



# Contents of the carotid triangle







- 28. Common carotid artery
- 29. Internal carotid artery
- 30. External carotid artery
- 31. Superior thyroid artery
- 32. External branch of the superior laryngeal nerve
- 33. Thyrohyoid
- 34. Superior laryngeal artery
- 35. Internal branch of the superior laryngeal nerve
- 36. Thyrohyoid membrane

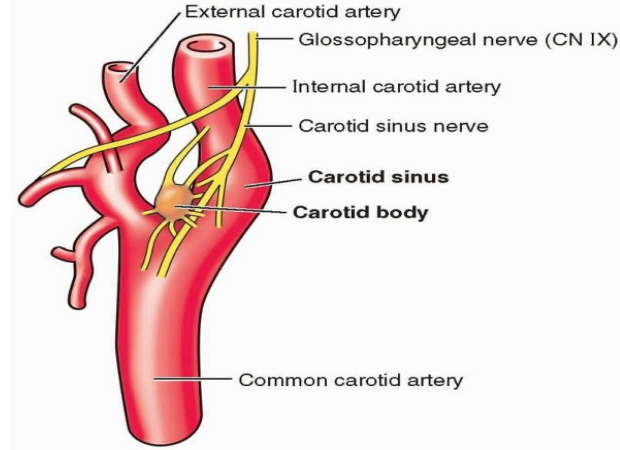
# Carotid triangle continued:

## Contents:

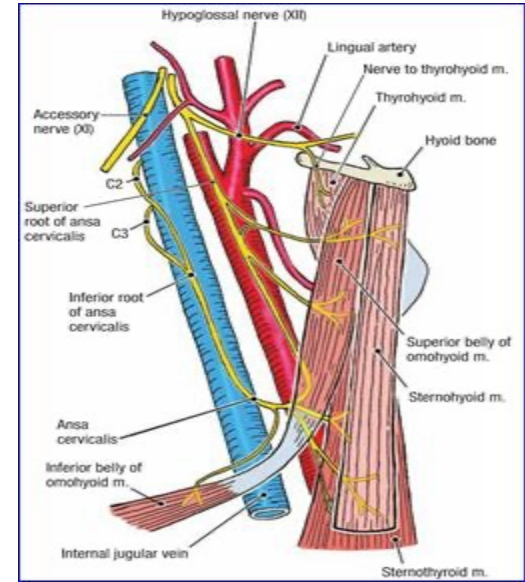
- a. common carotid artery
  - internal carotid artery
  - external carotid artery
- b. internal jugular vein
- c. vagus N (CN X)
- d. ansa cervicalis

## Carotid Sinus and Carotid Body

- Carotid sinus: BP regulator, CN IX
- Carotid body: Chemoreceptor, CN IX

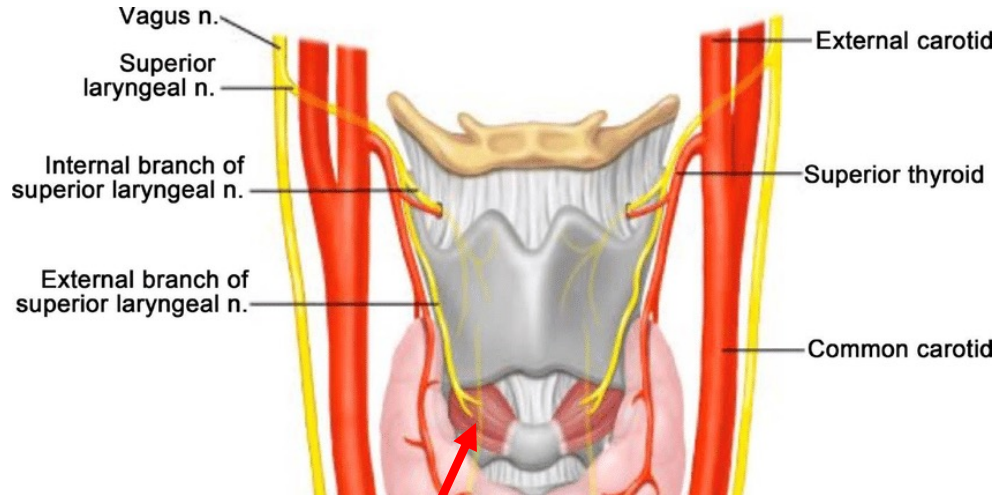


Medial view of right carotid artery

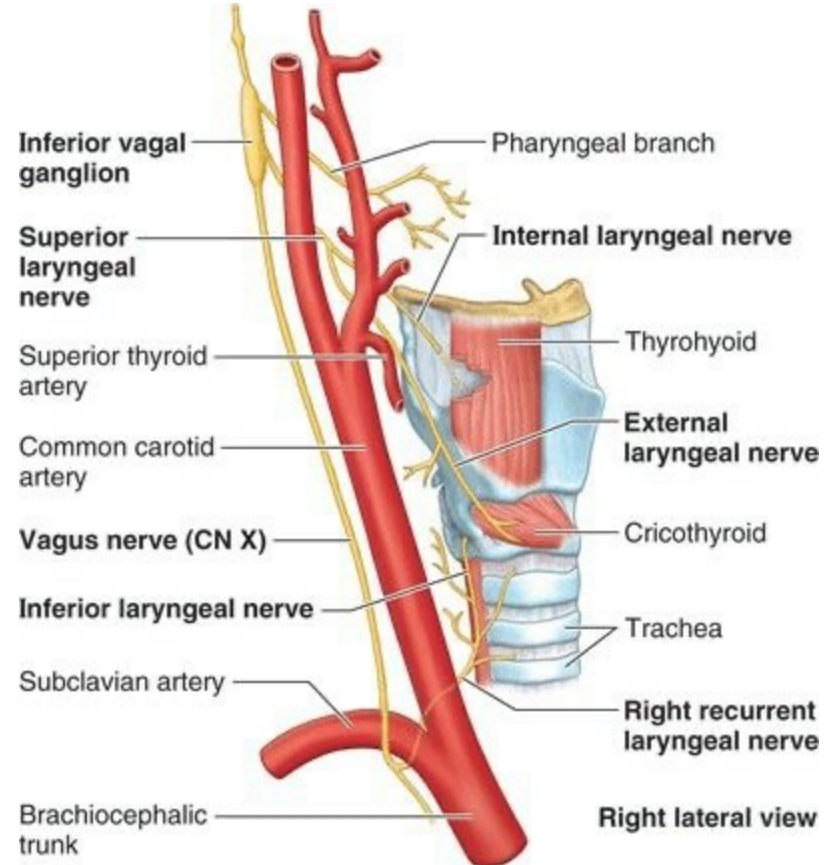




# Branching of the superior laryngeal nerve (SLN)



**Cricothyroid muscle – the only tensor muscle of the larynx**



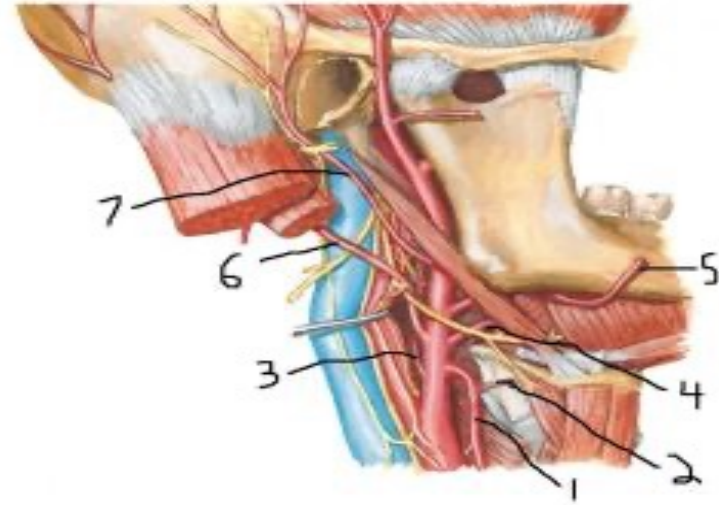
## **Ascending pharyngeal artery (#3)**

- a. pharyngeal**
- b. meningeal**
- c. inferior tympanic (to tympanic cavity)**

## **Lingual artery (#4)**

**travels deep to hypoglossal nerve (CN XII) to the muscles of tongue.**

## **Facial artery (#5)**



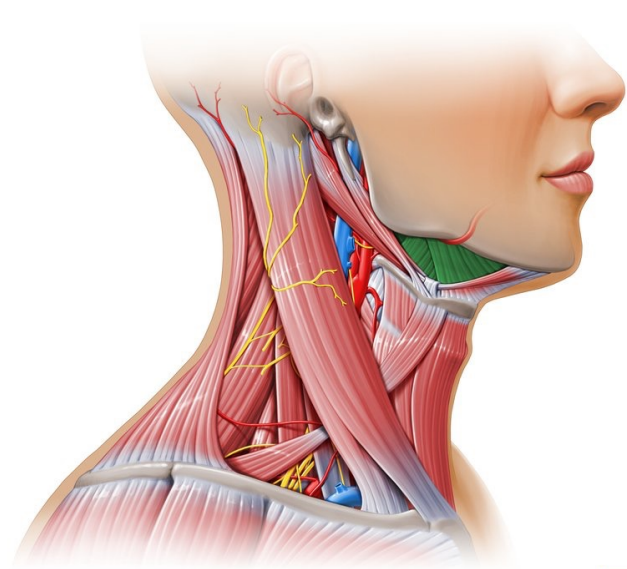
# 3. Submandibular Triangle

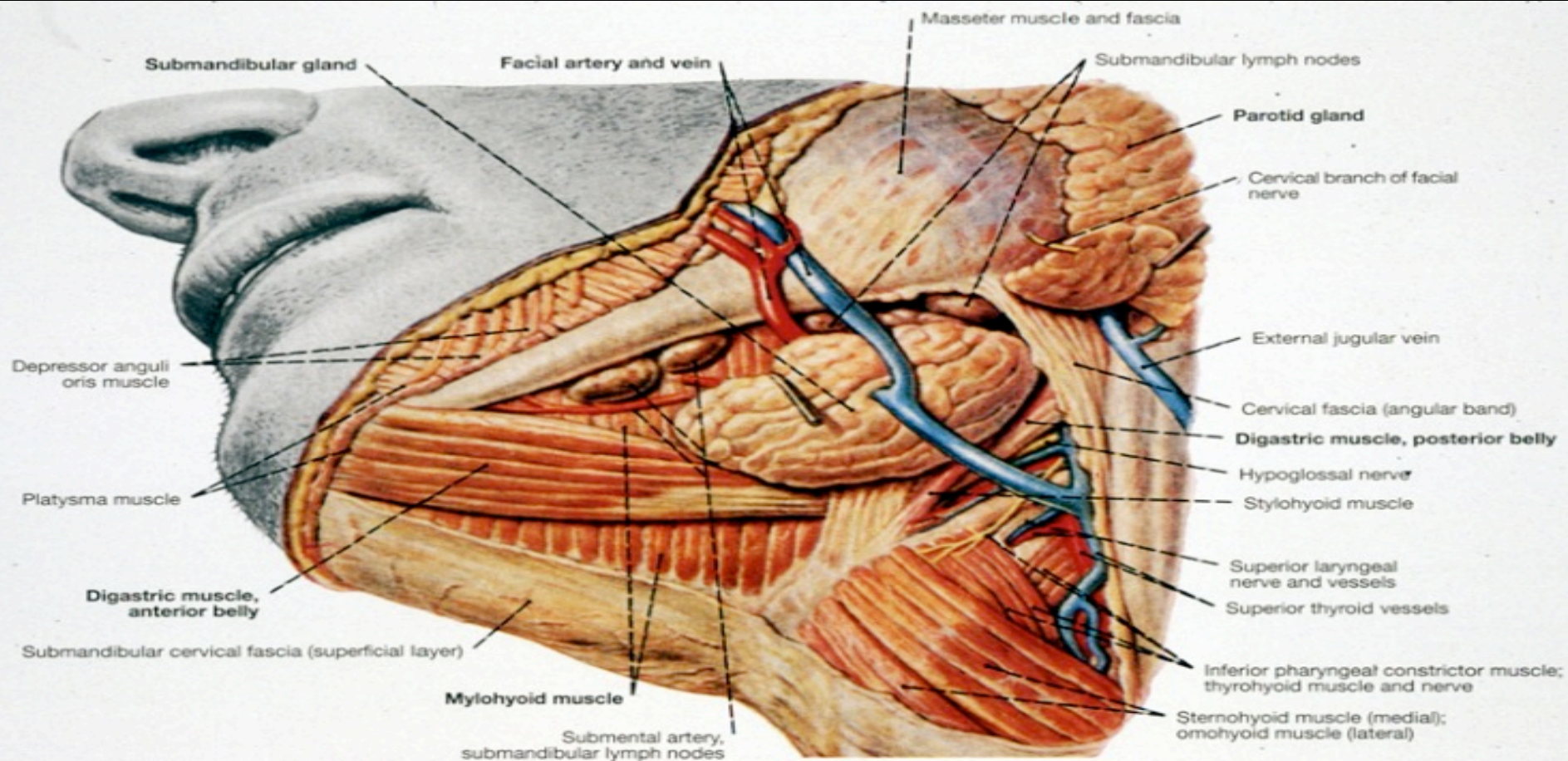
Boundaries:

<b>Superior:</b>	<b>Inferior border of mandible</b>
<b>Anterior:</b>	<b>Anterior belly of digastric muscle</b>
<b>Posterior:</b>	<b>Posterior belly of digastric muscle</b>

Contents:

- a. SMG (submandibular gland)**
- b. lymph nodes (submandibular group)**
- c. facial artery**
- d. facial vein**

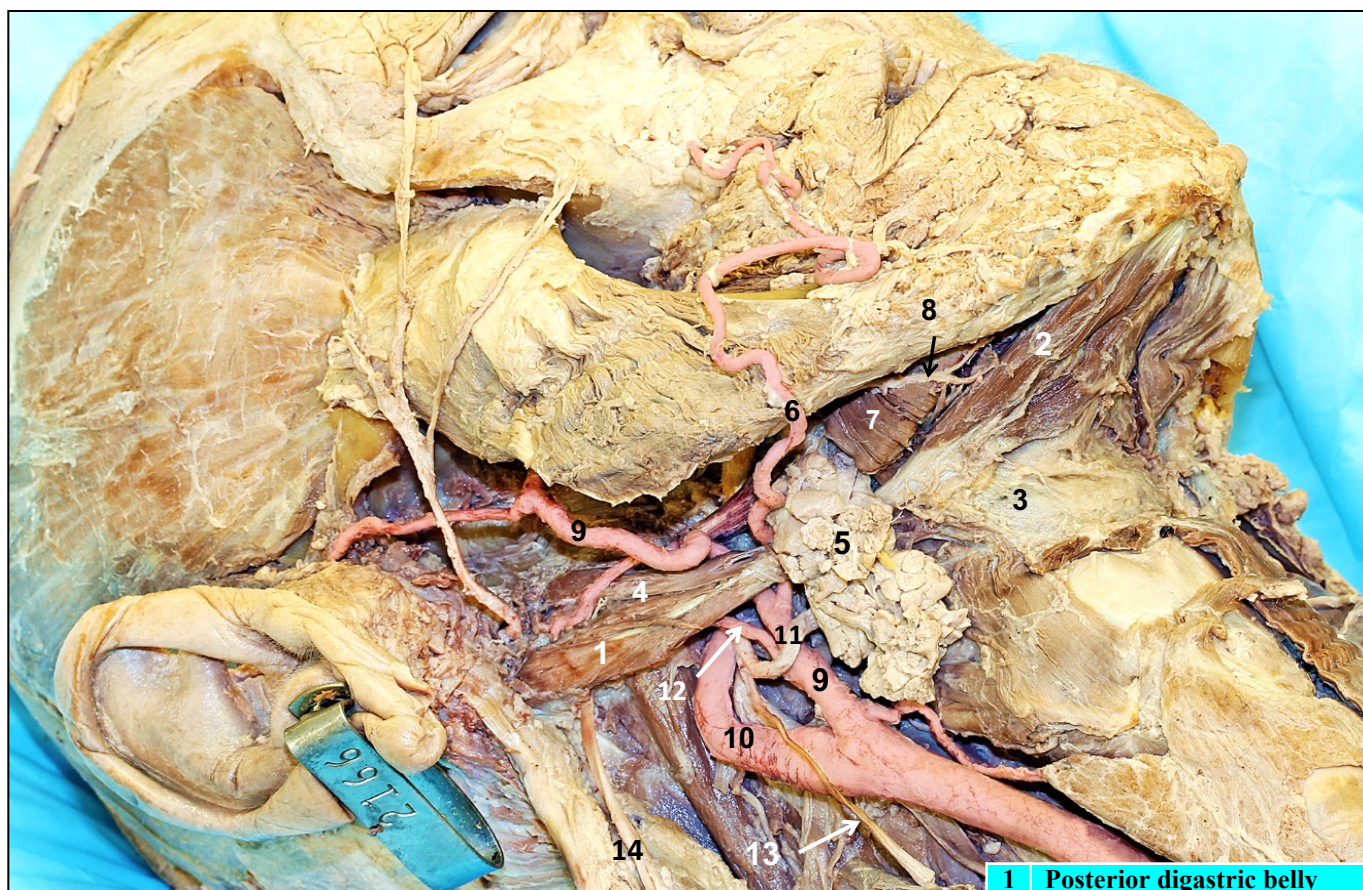




**Fig. 726: The Left Submandibular Triangle and Submandibular Gland (Viewed from Below)**

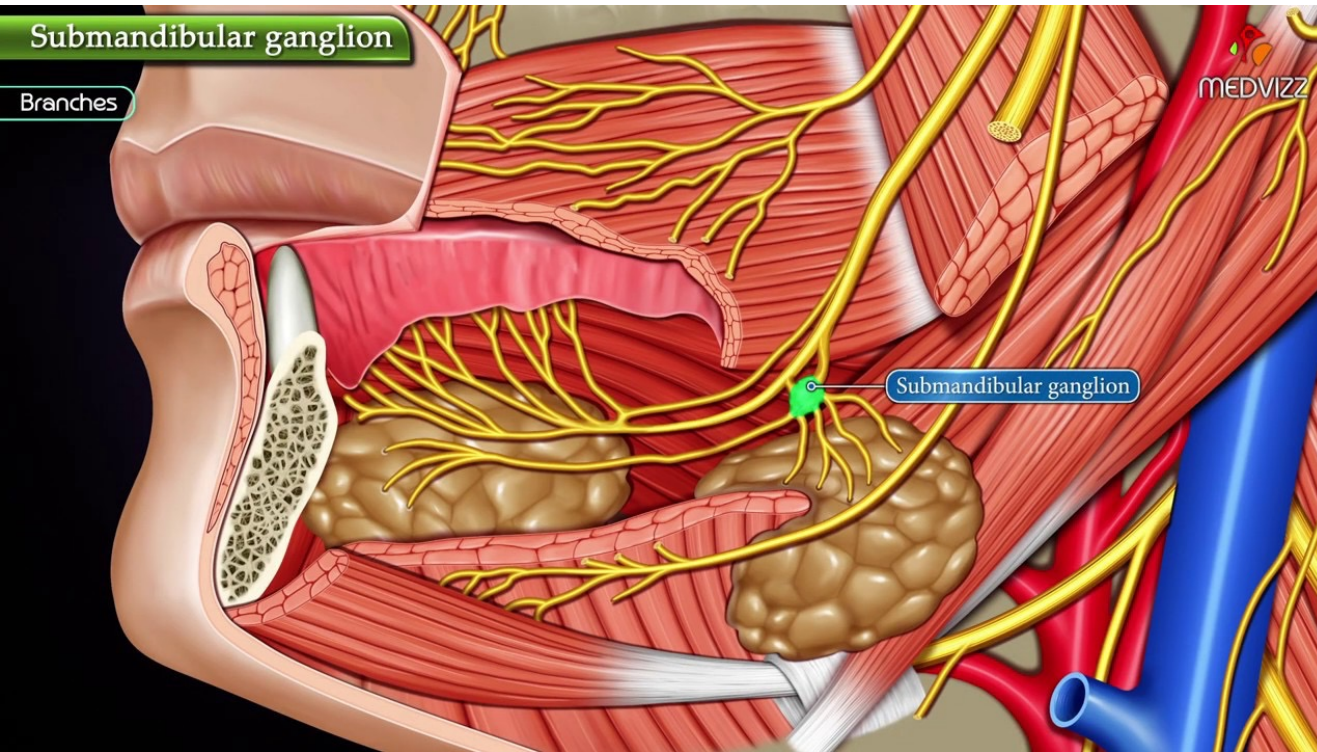


# Submandibular triangle



1	Posterior digastric belly	8	Mylohyoid nerve
2	Anterior digastric belly	9	External carotid artery
3	Hyoid bone	10	Internal carotid artery
4	Stylohyoid muscle	11	Hypoglossal nerve
5	Submandibular gland	12	Occipital artery
6	Facial artery	13	Ansa cervicalis
7	Mylohyoid muscle	14	Accessory nerve

# Innervation of submandibular and sublingual glands





# Innovation for SMG and SLG



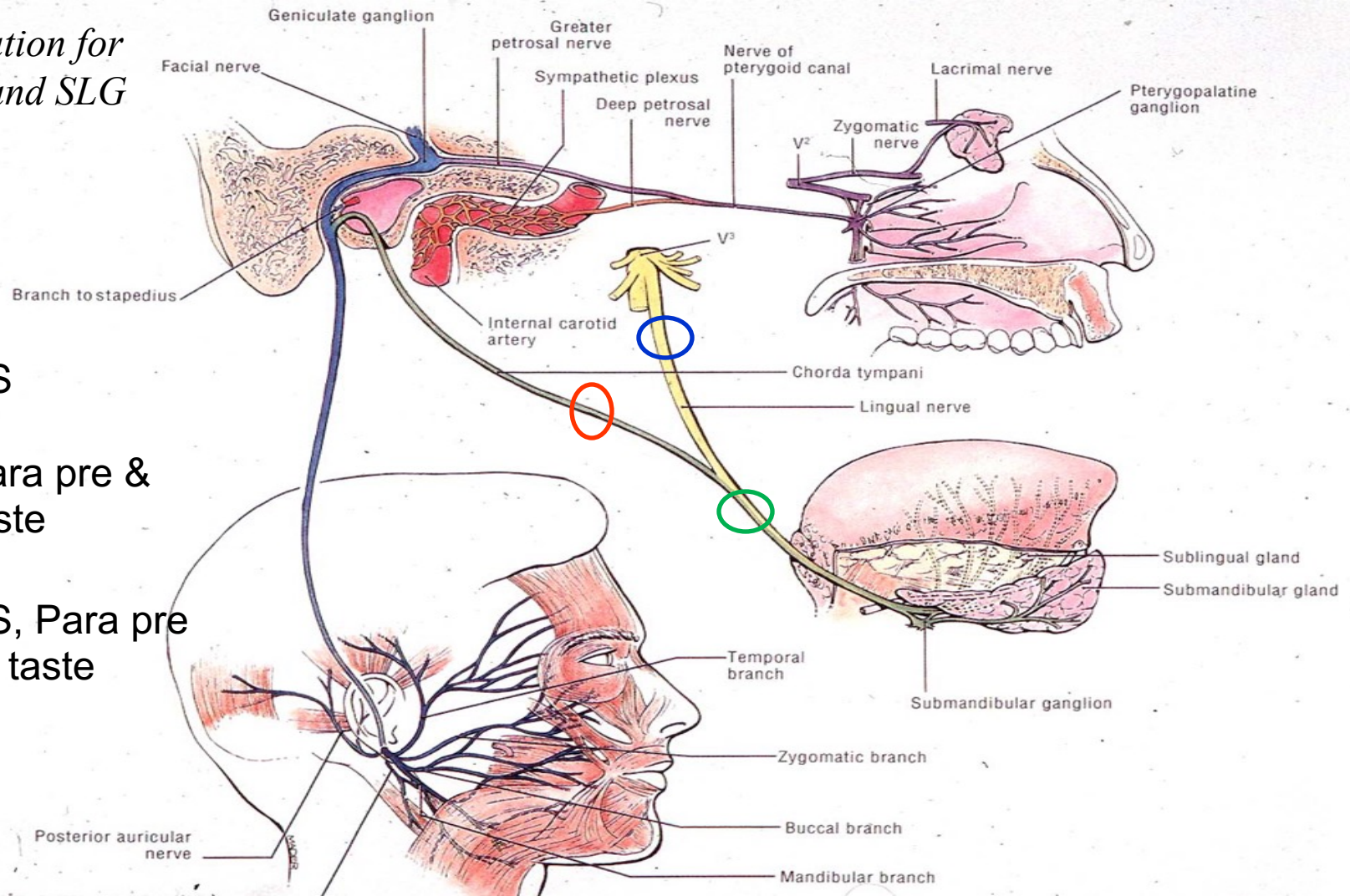
SS

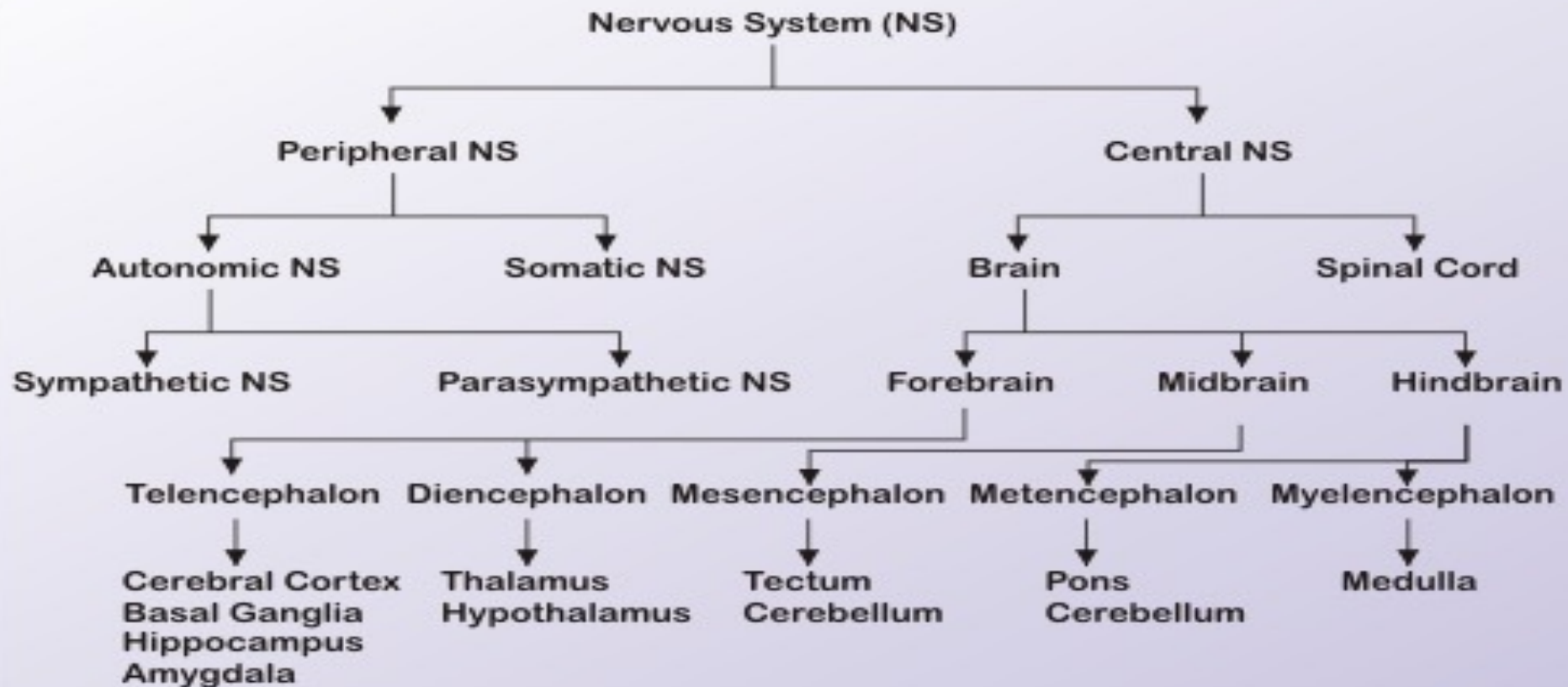


Para pre &  
taste



SS, Para pre  
& taste

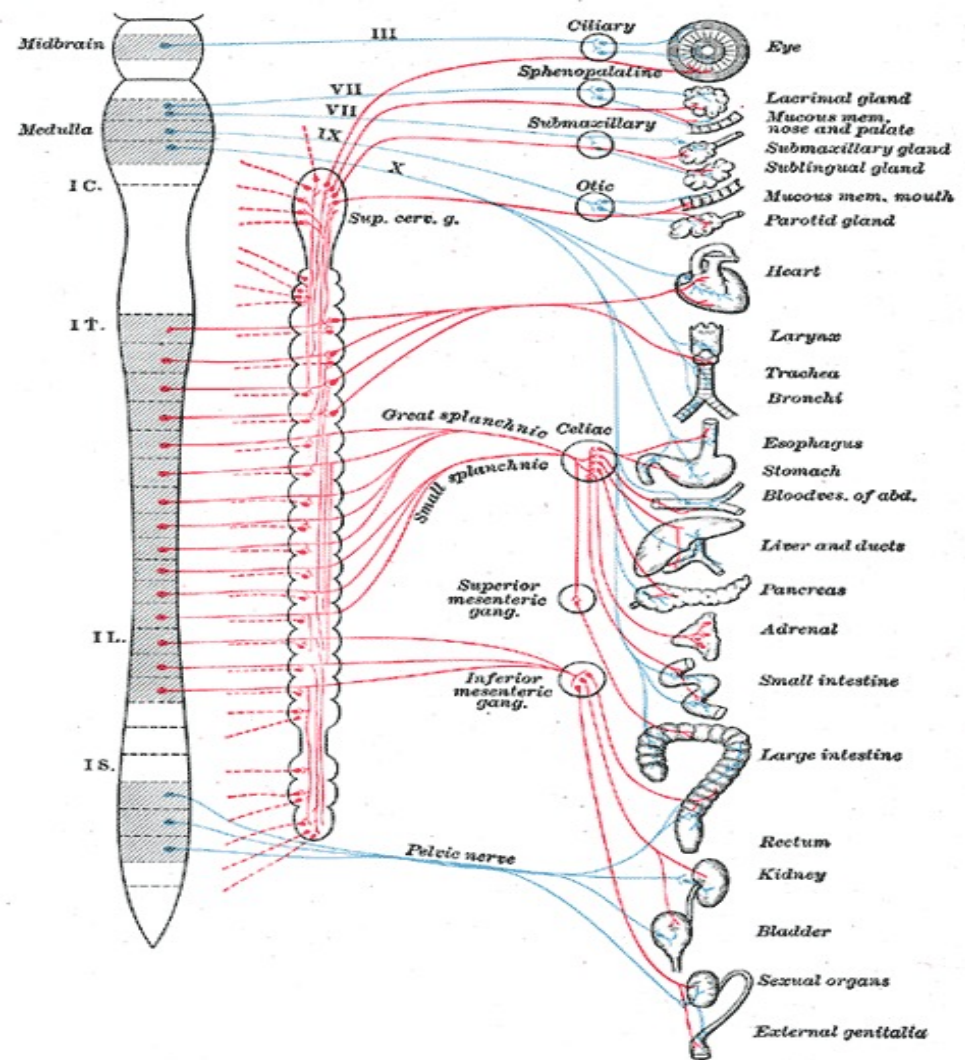




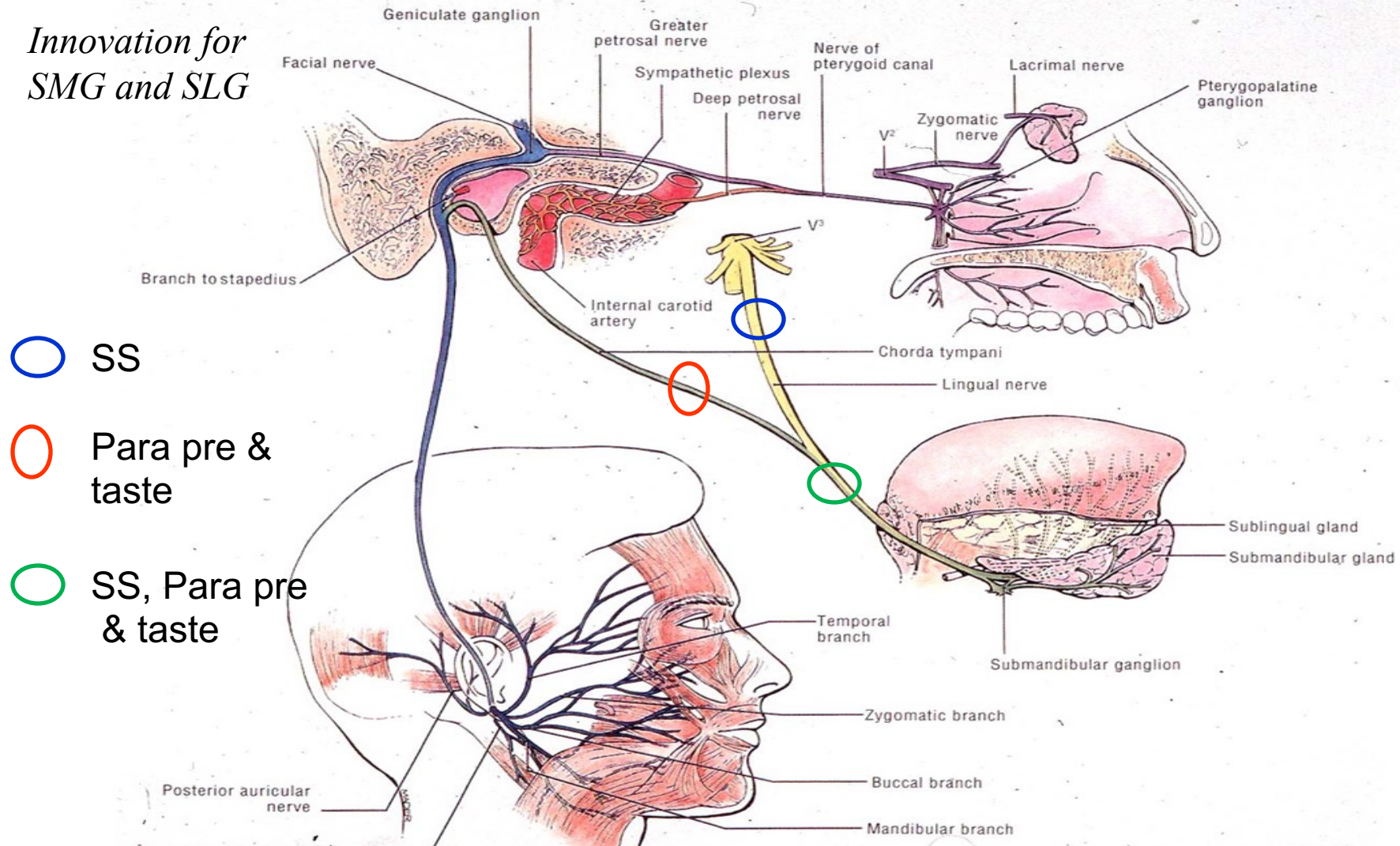


# Autonomic nervous system

1. Peripheral nervous system
2. Influences the function of internal organs
3. Control of respiration, cardiac regulation, vasomotor, and reflex actions (coughing, sneezing, etc.)
4. ANS is divided into sympathetic (T1-L2) and parasympathetic [craniosacral, (CN III, CN VII, CN IX & CN X, S2-4)] nervous system.
5. Sequential two-neuron efferent pathway

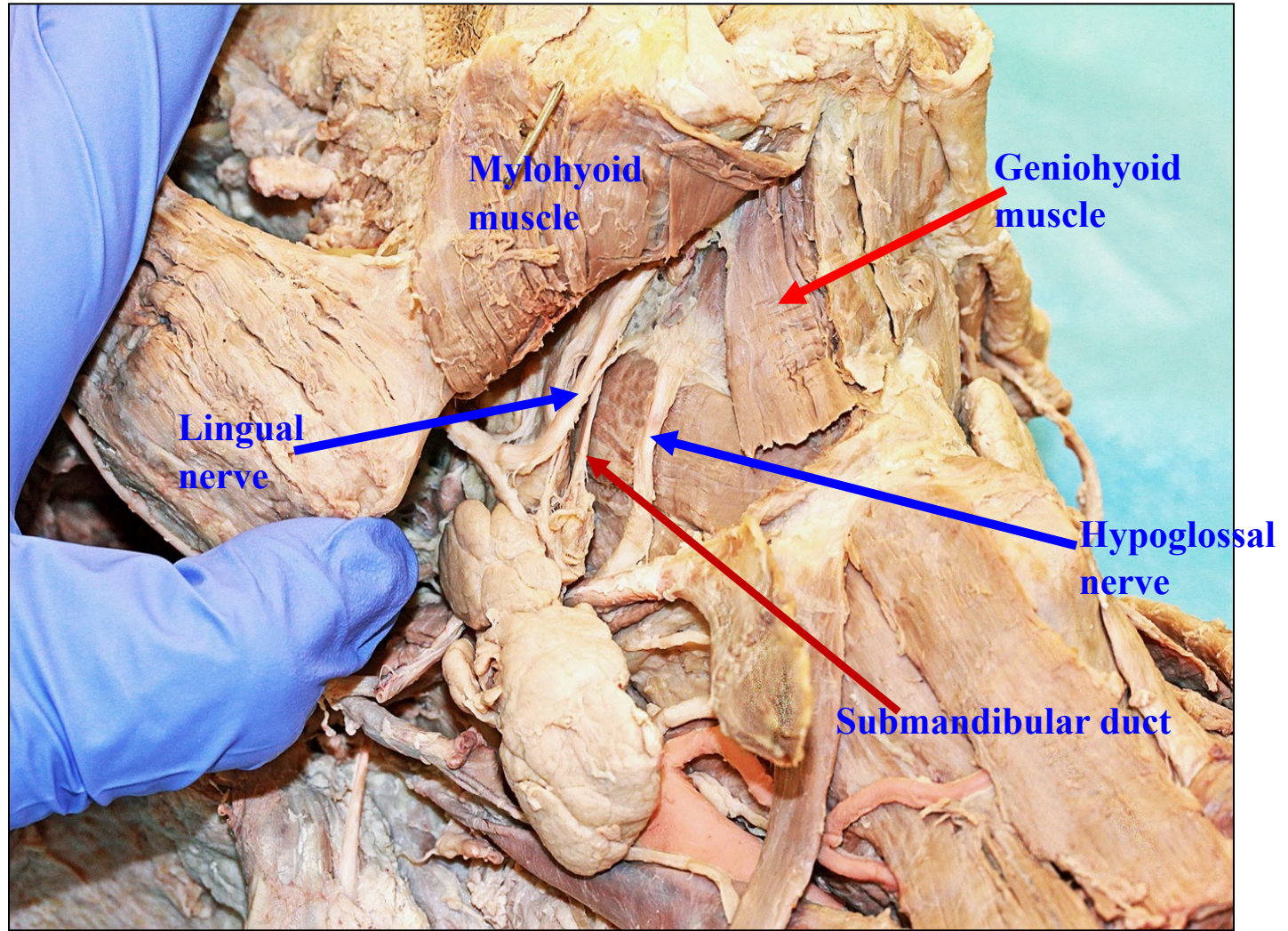


# Innovation for SMG and SLG



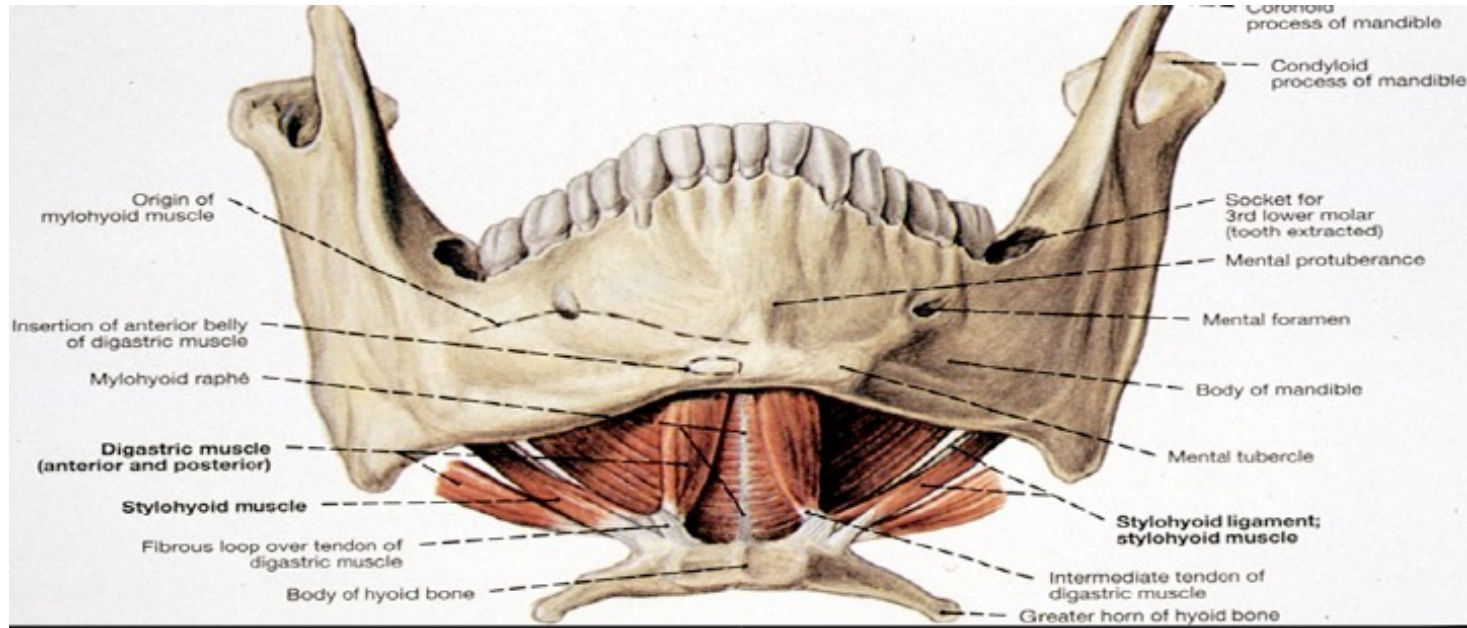


## Exposure of the submandibular triangle





# 4. Submental Triangle

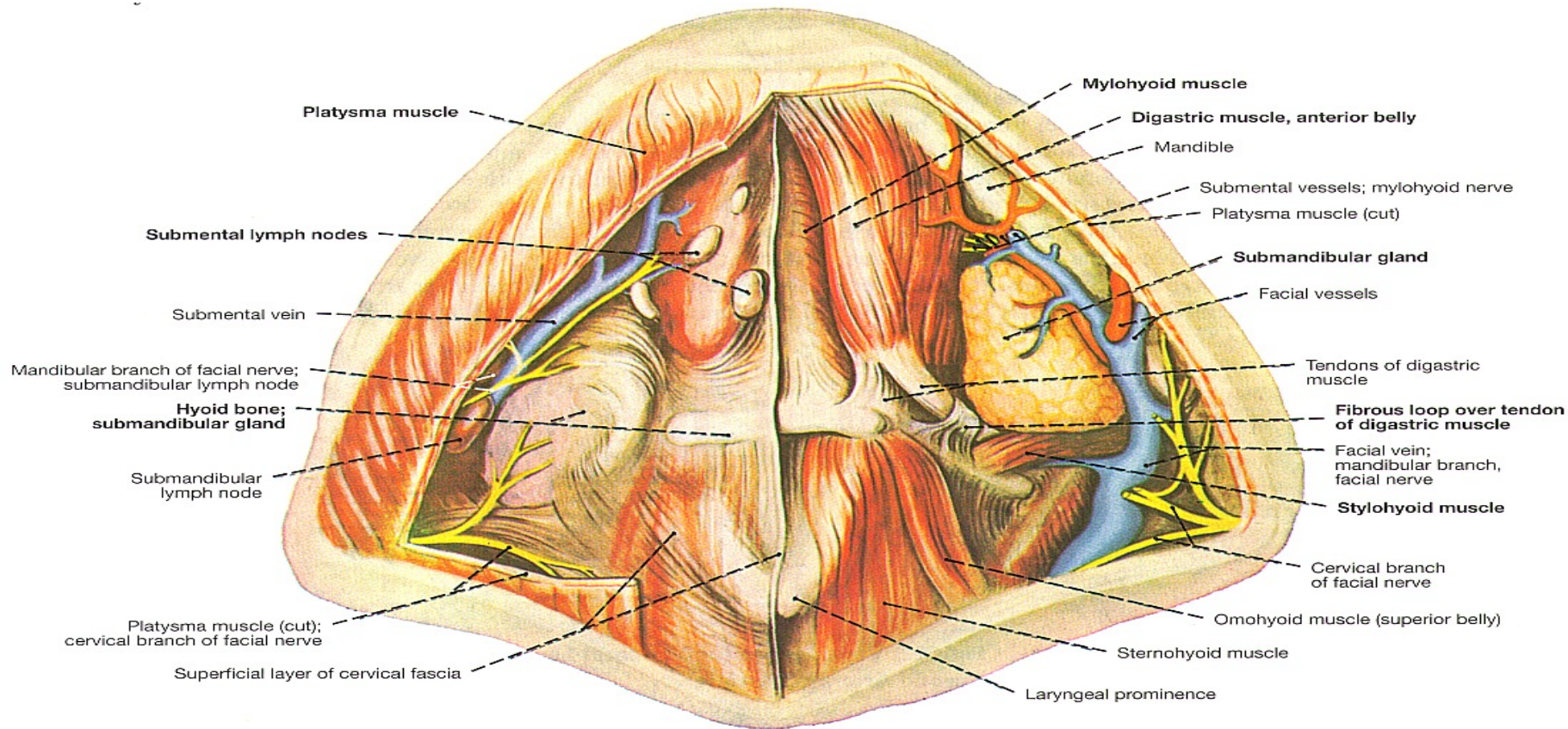


Boundaries:

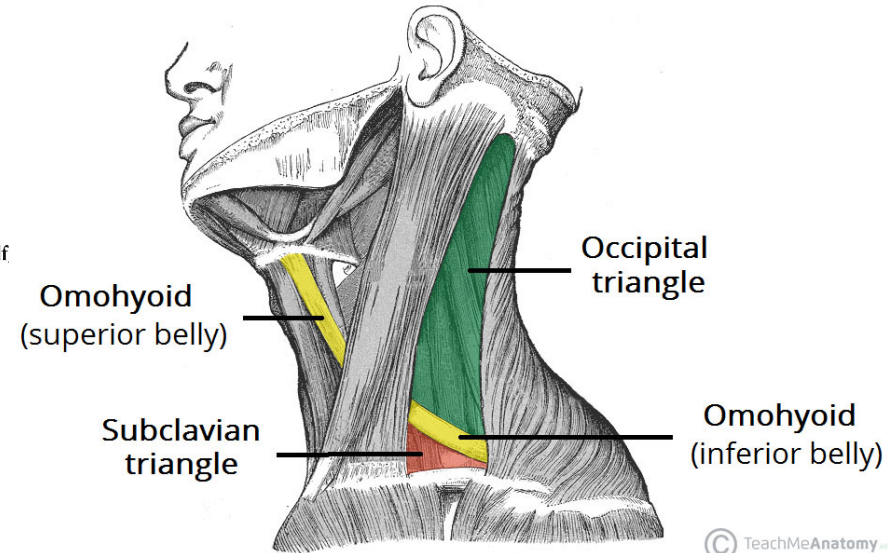
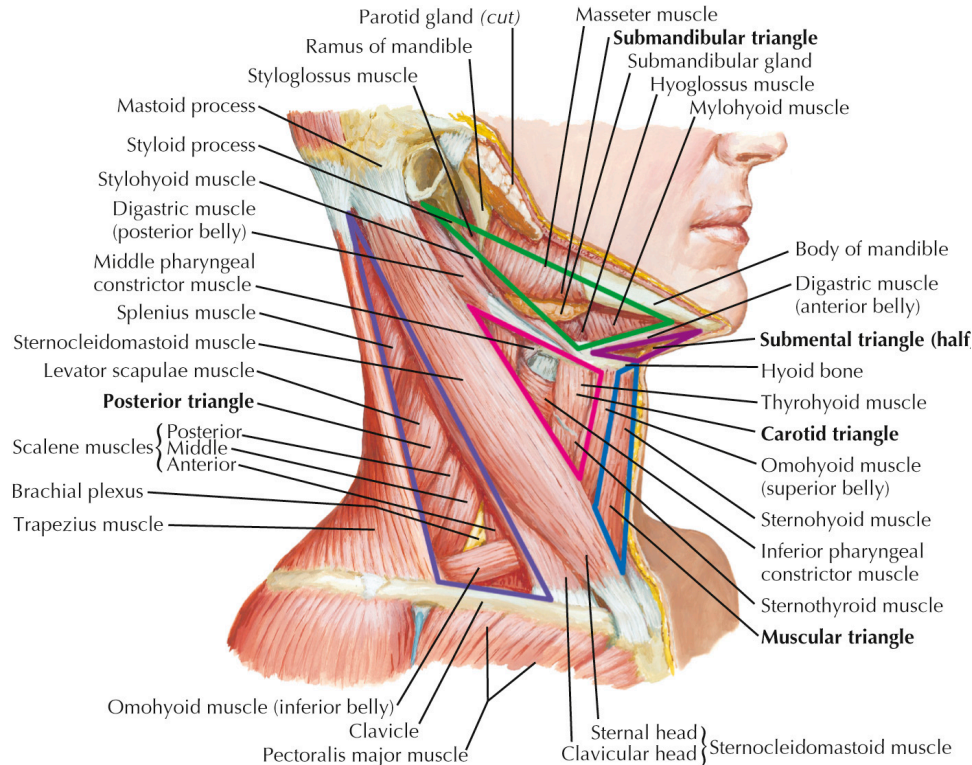
Lateral: both anterior bellies of digastric muscle

Inferior: hyoid bone

# Submental Triangle



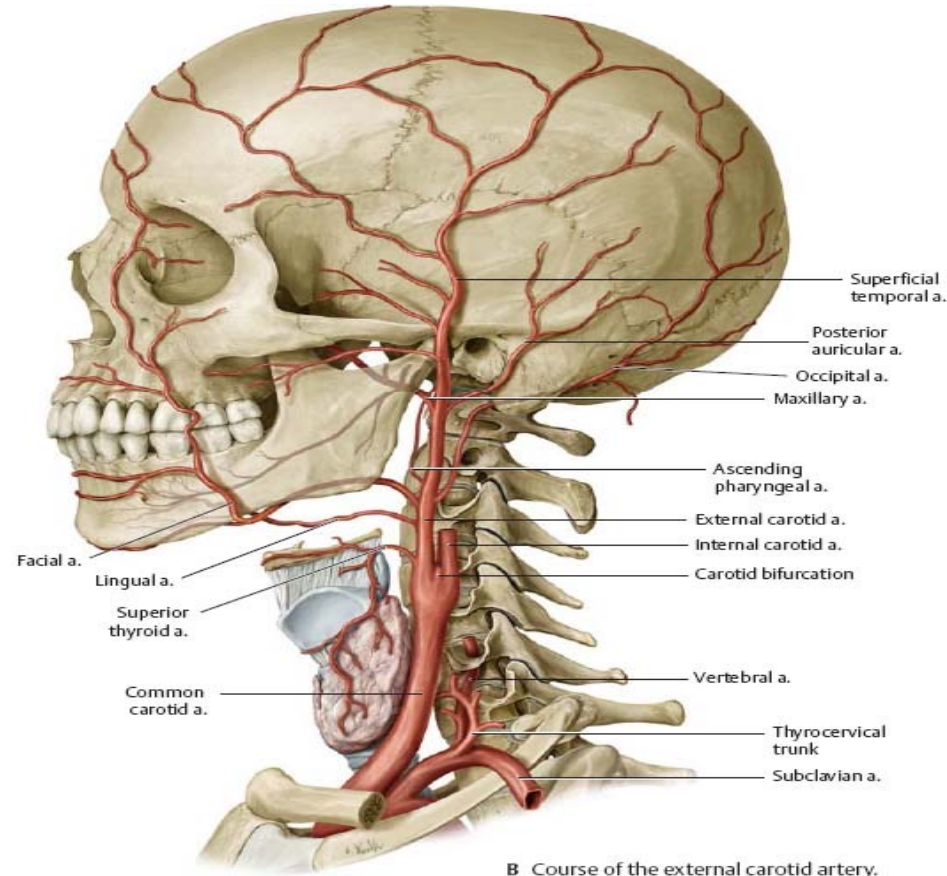
# Posterior triangle of the neck





# Branches of External Carotid Artery

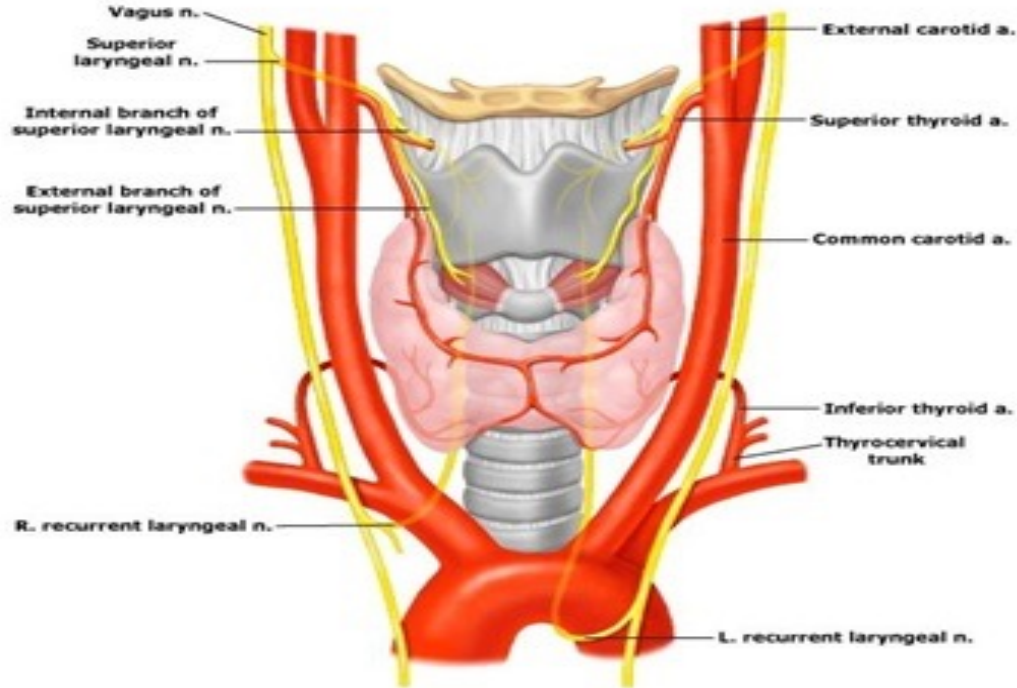
1. Superior Thyroid Artery
2. Ascending Pharyngeal Artery
3. Lingual Artery
4. Facial Artery
5. Occipital Artery
6. Posterior Auricular Artery
7. Maxillary Artery
8. Superficial Temporal Artery



B Course of the external carotid artery.

# Branches of External Carotid Artery

## Superior thyroid artery



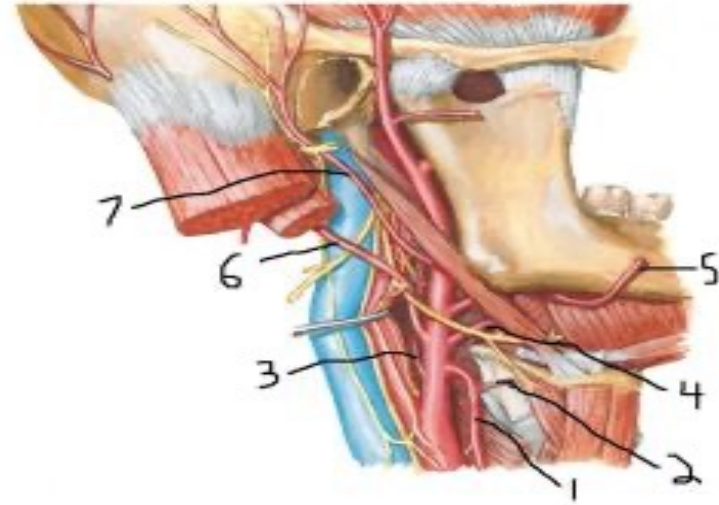
## **Ascending pharyngeal artery (#3)**

- a. pharyngeal**
- b. meningeal**
- c. inferior tympanic (to tympanic cavity)**

## **Lingual artery (#4)**

**travels deep to hypoglossal nerve (CN XII) to the muscles of tongue.**

## **Facial artery (#5)**





Occipital artery (#6)

Posterior auricular artery (#7)

Maxillary artery

Superficial temporal artery

Terminal branches of the  
external carotid artery

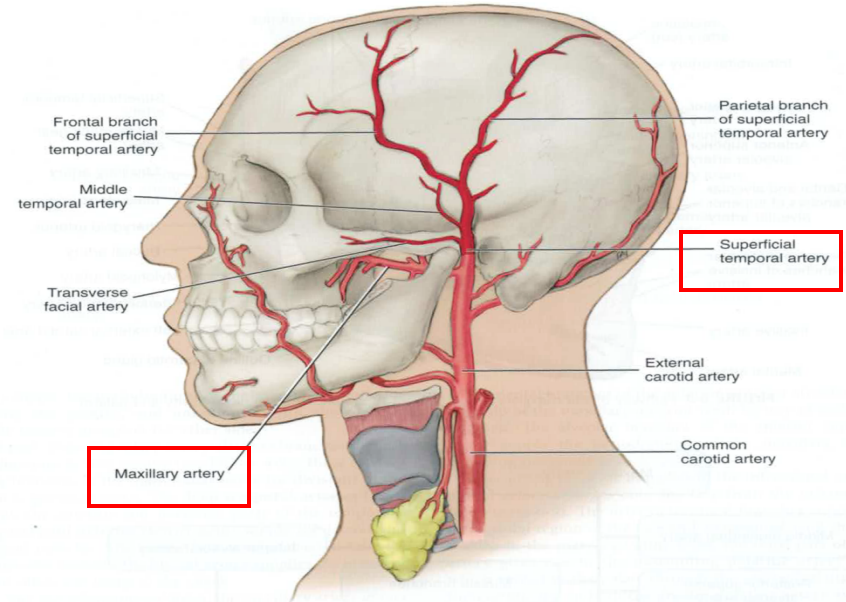
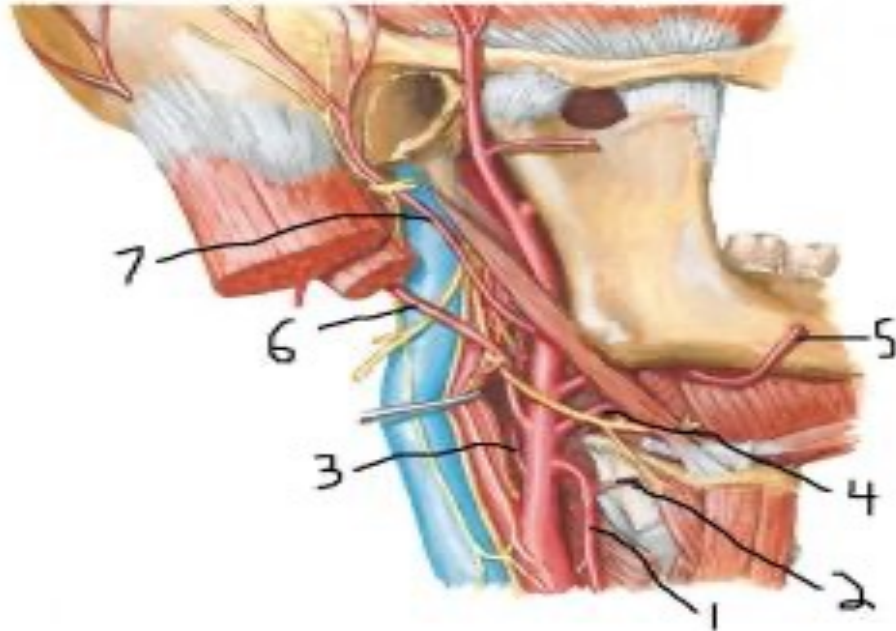
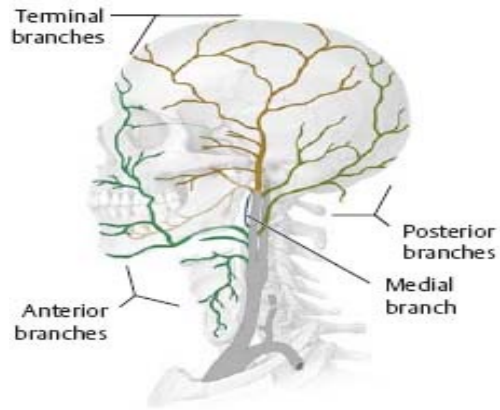
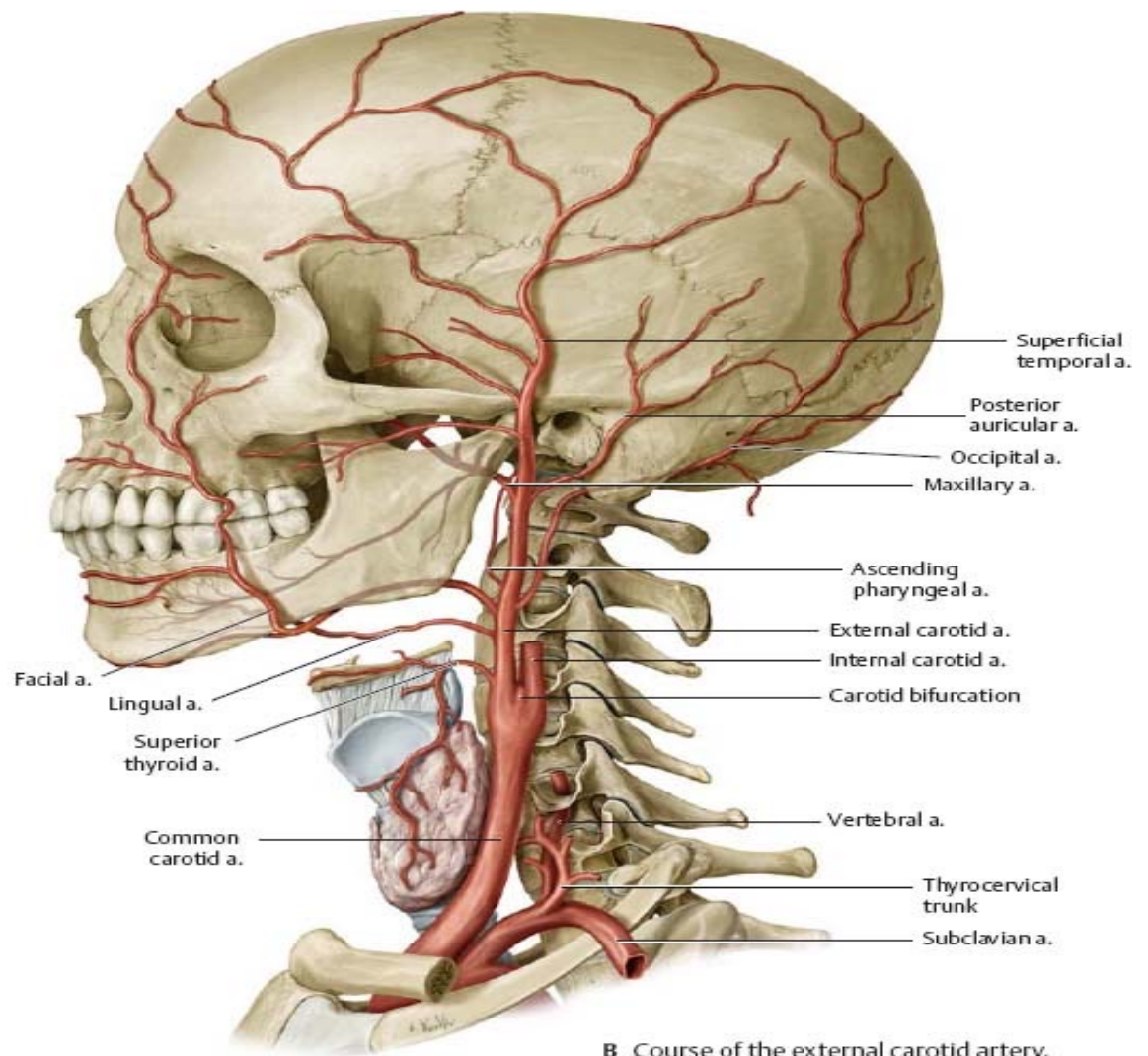


FIGURE 6-8 Pathway of the superficial temporal artery.



A Schematic of the external carotid artery.

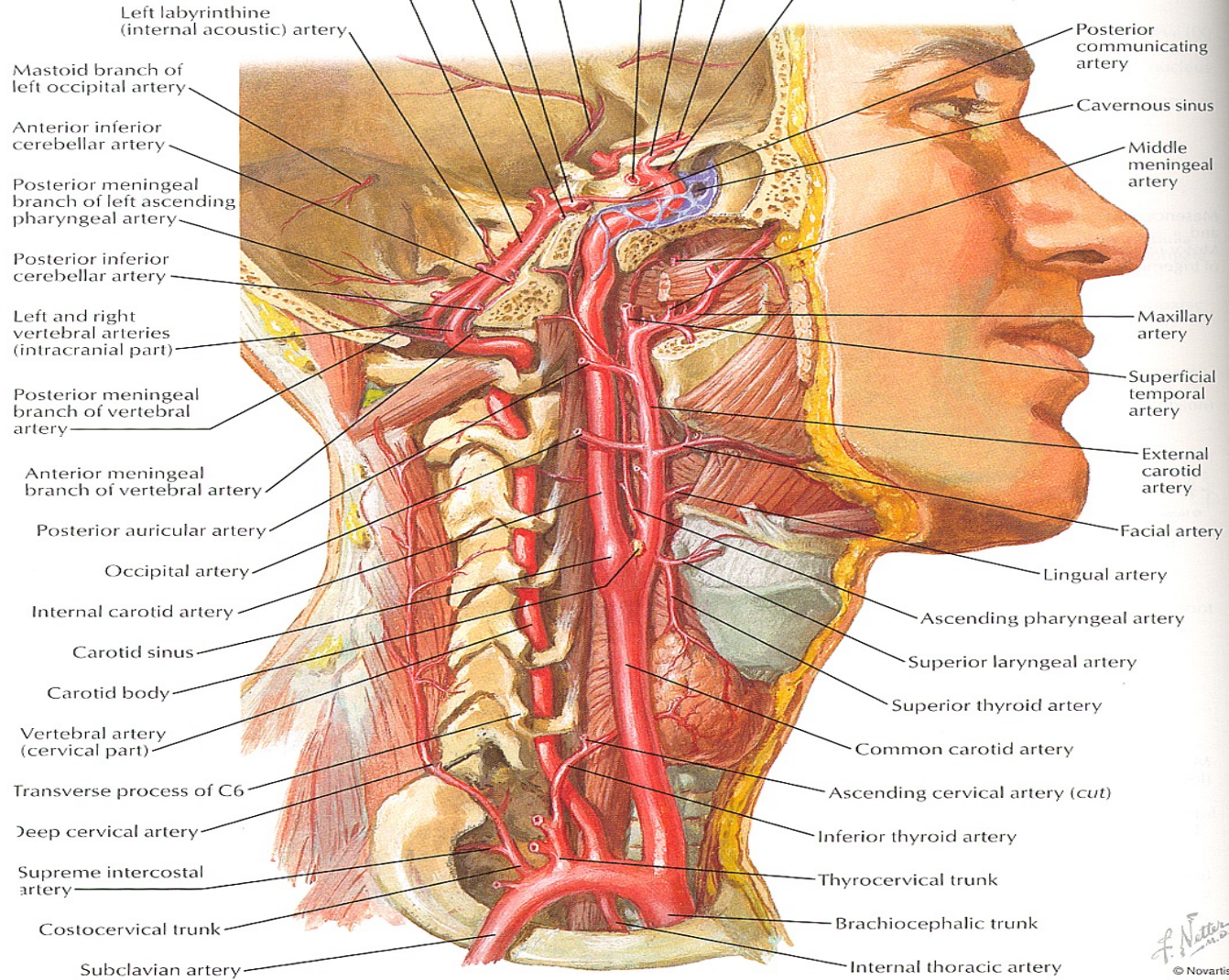
# *Branches of the external carotid artery*



B Course of the external carotid artery.

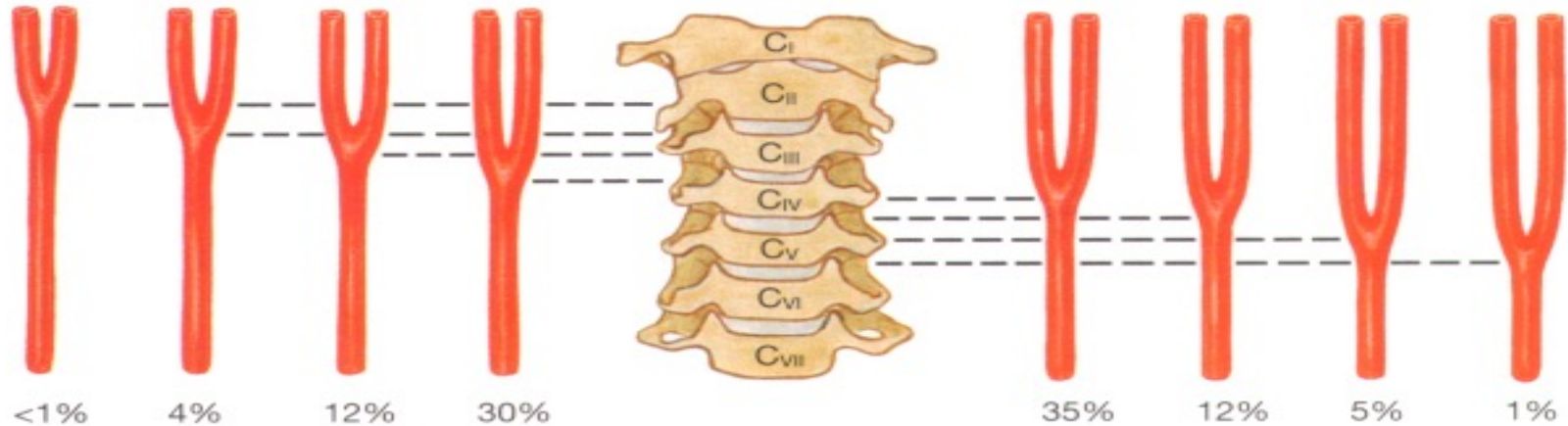


The carotid bifurcation is the point where the common carotid artery divides into internal and external carotid arteries

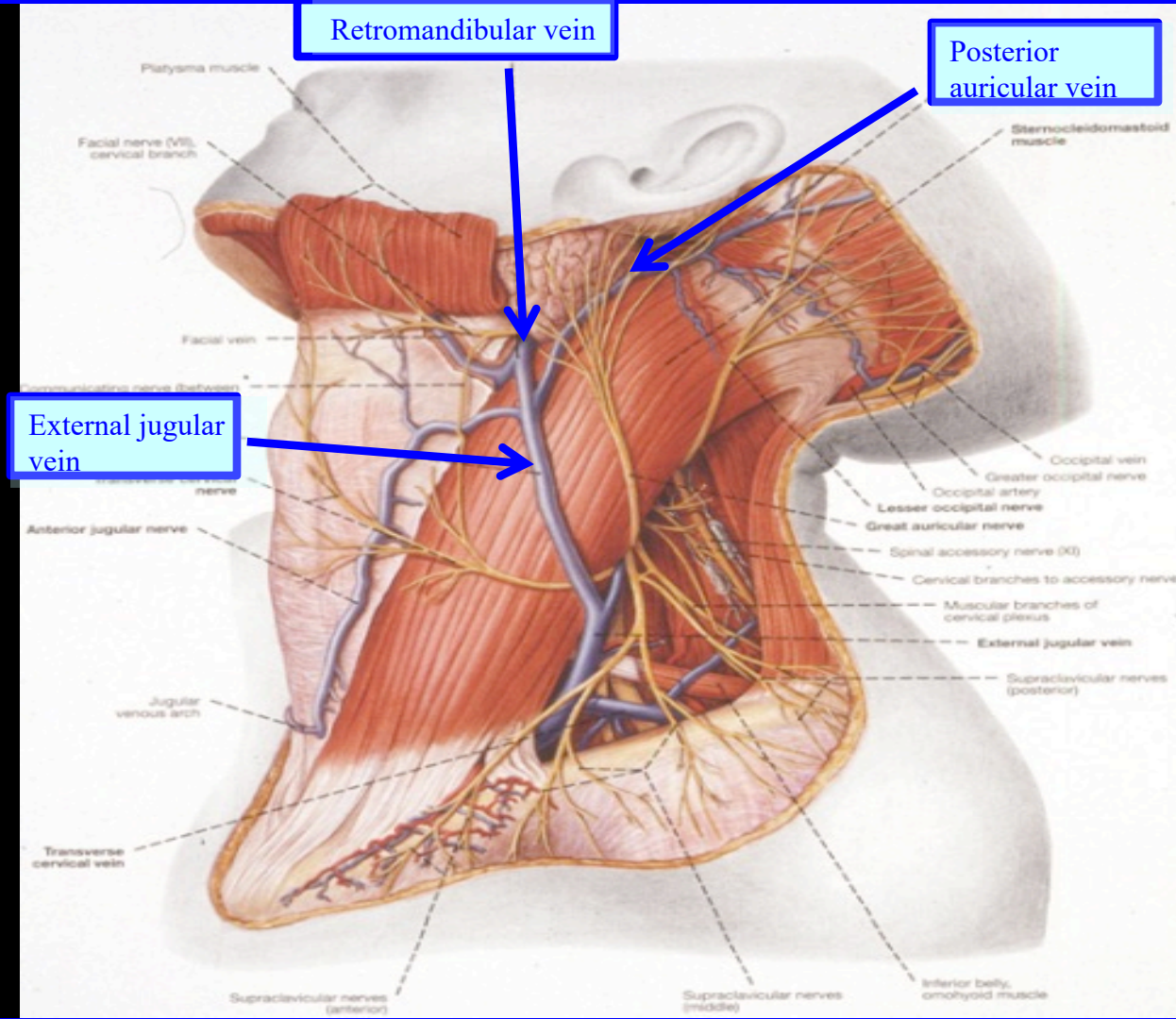




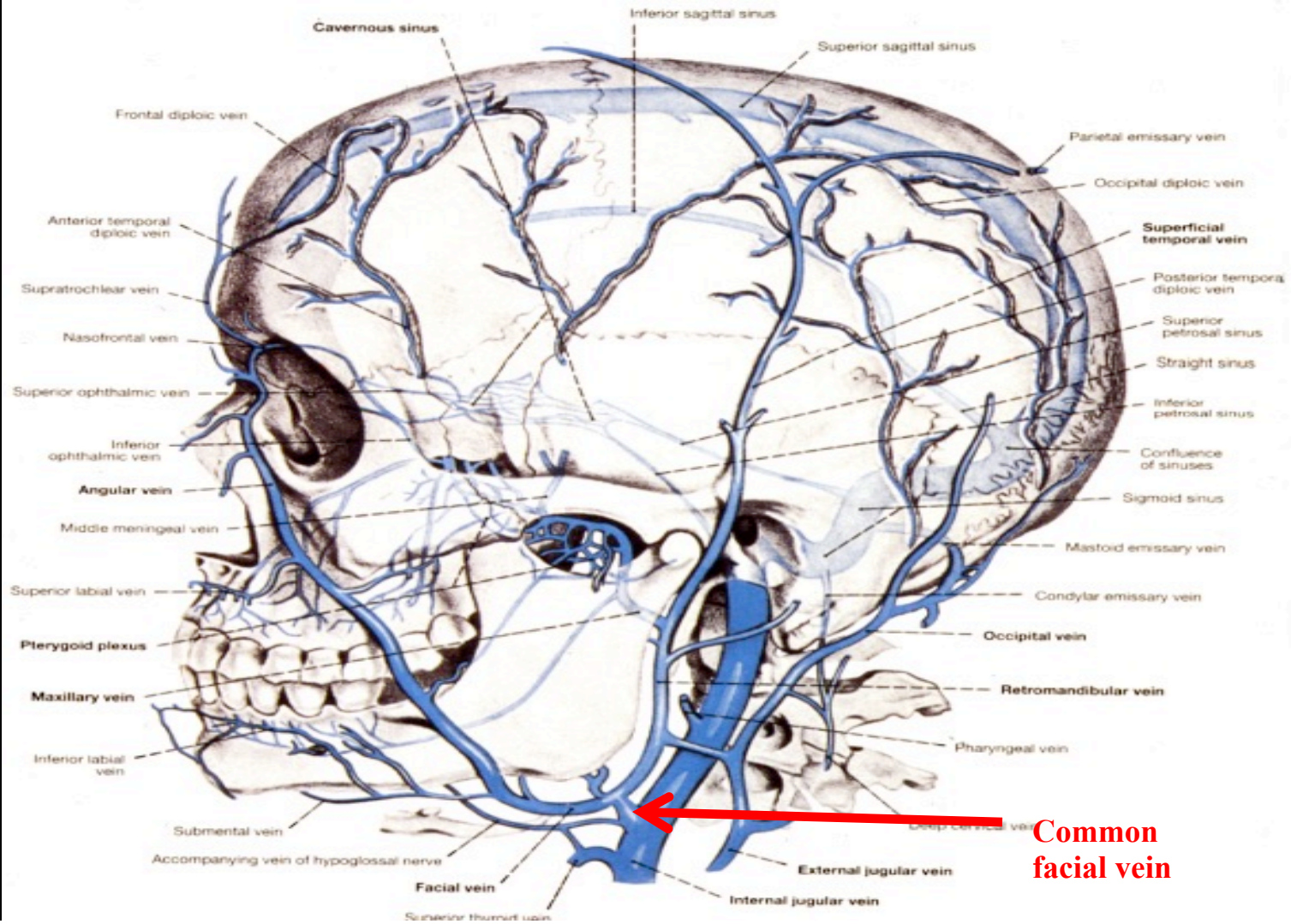
# Variation in carotid bifurcation anatomy



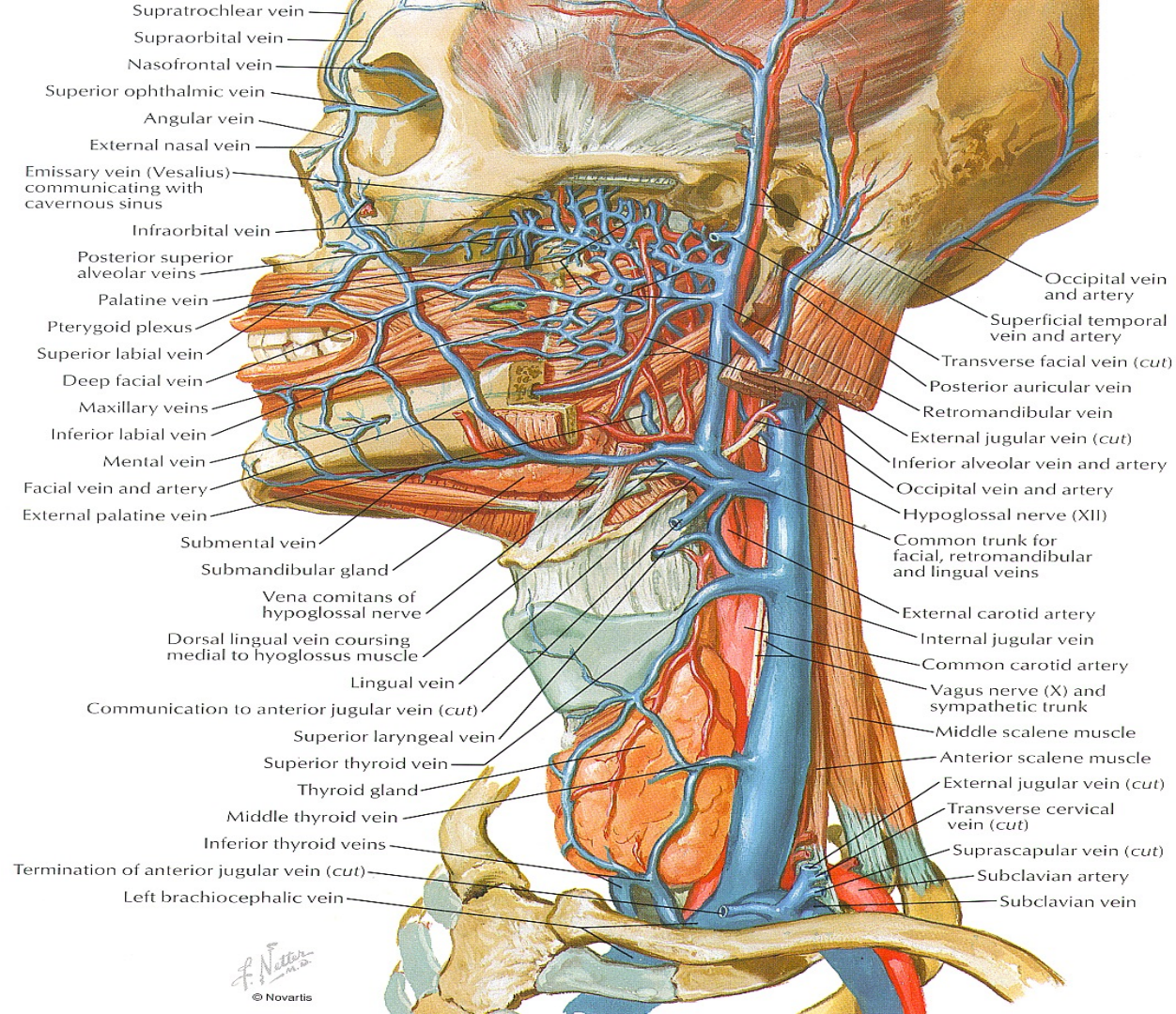
# Veins in the neck

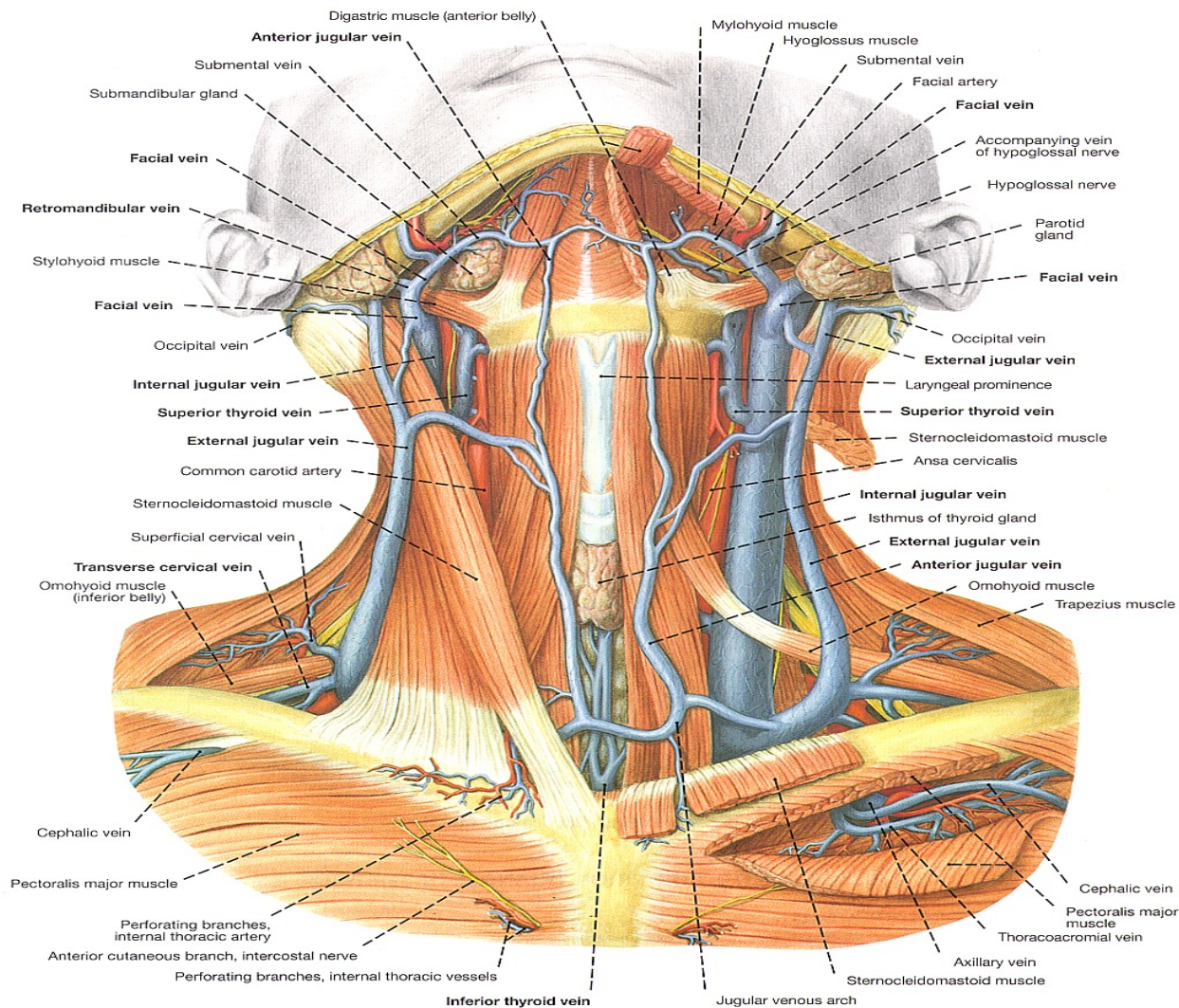


*Posterior  
auricular and  
retromandibular  
veins contribute  
to the external  
jugular vein*

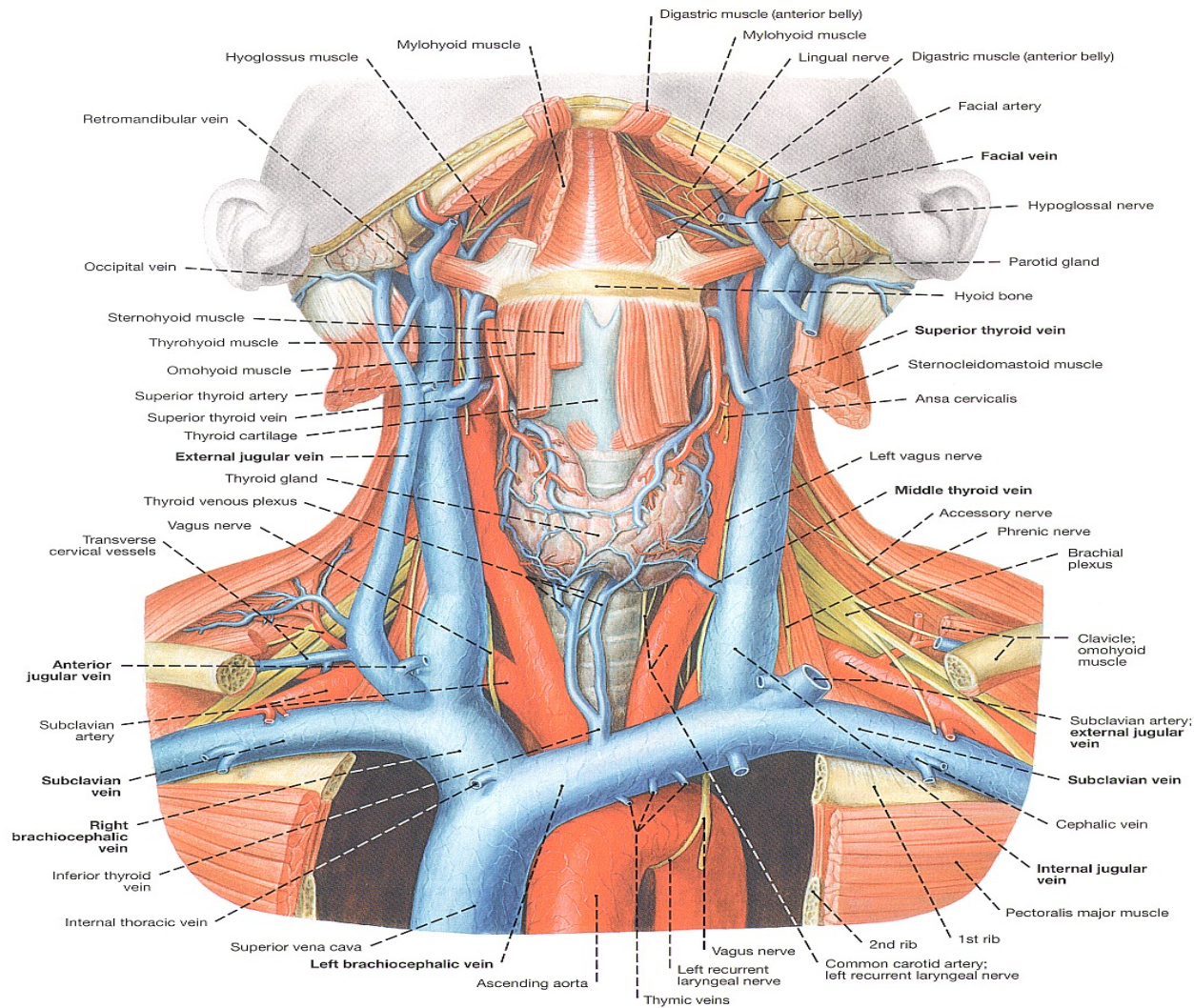






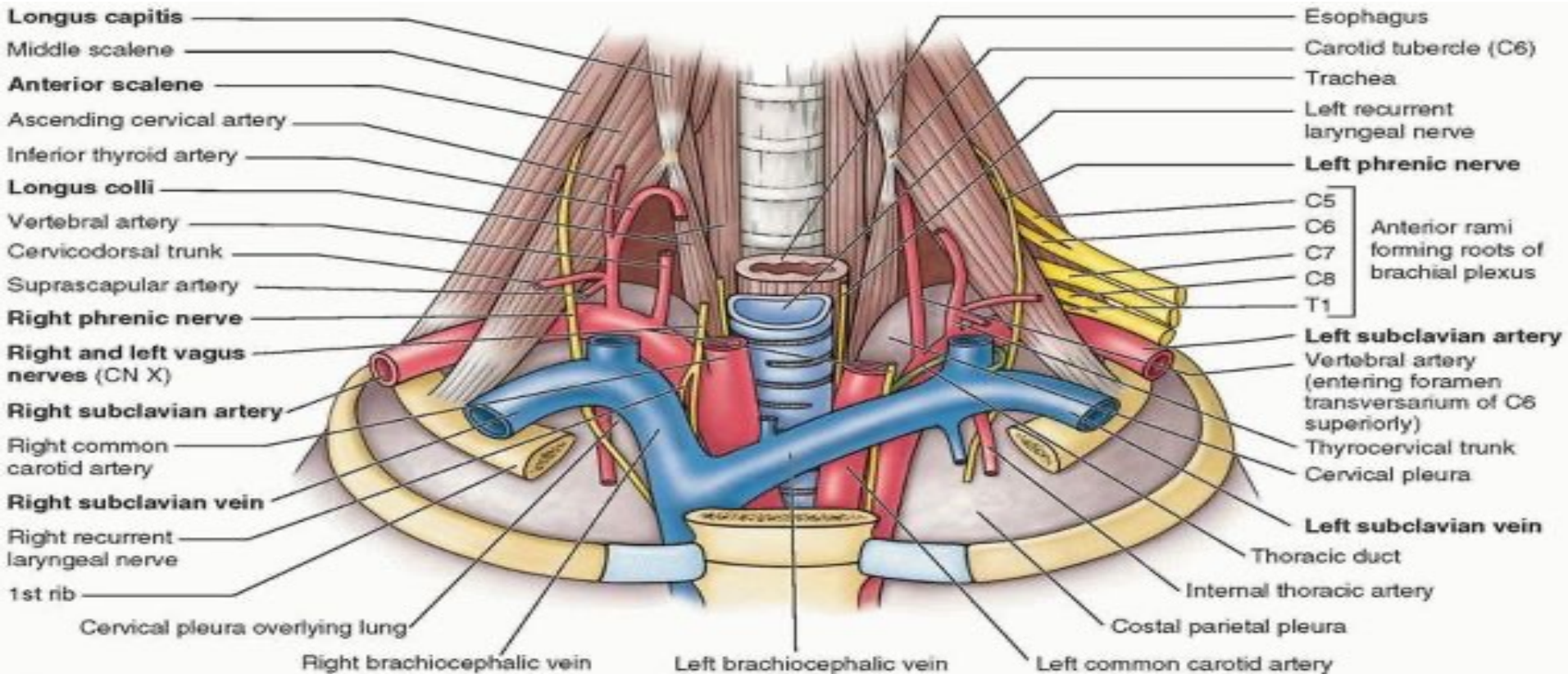






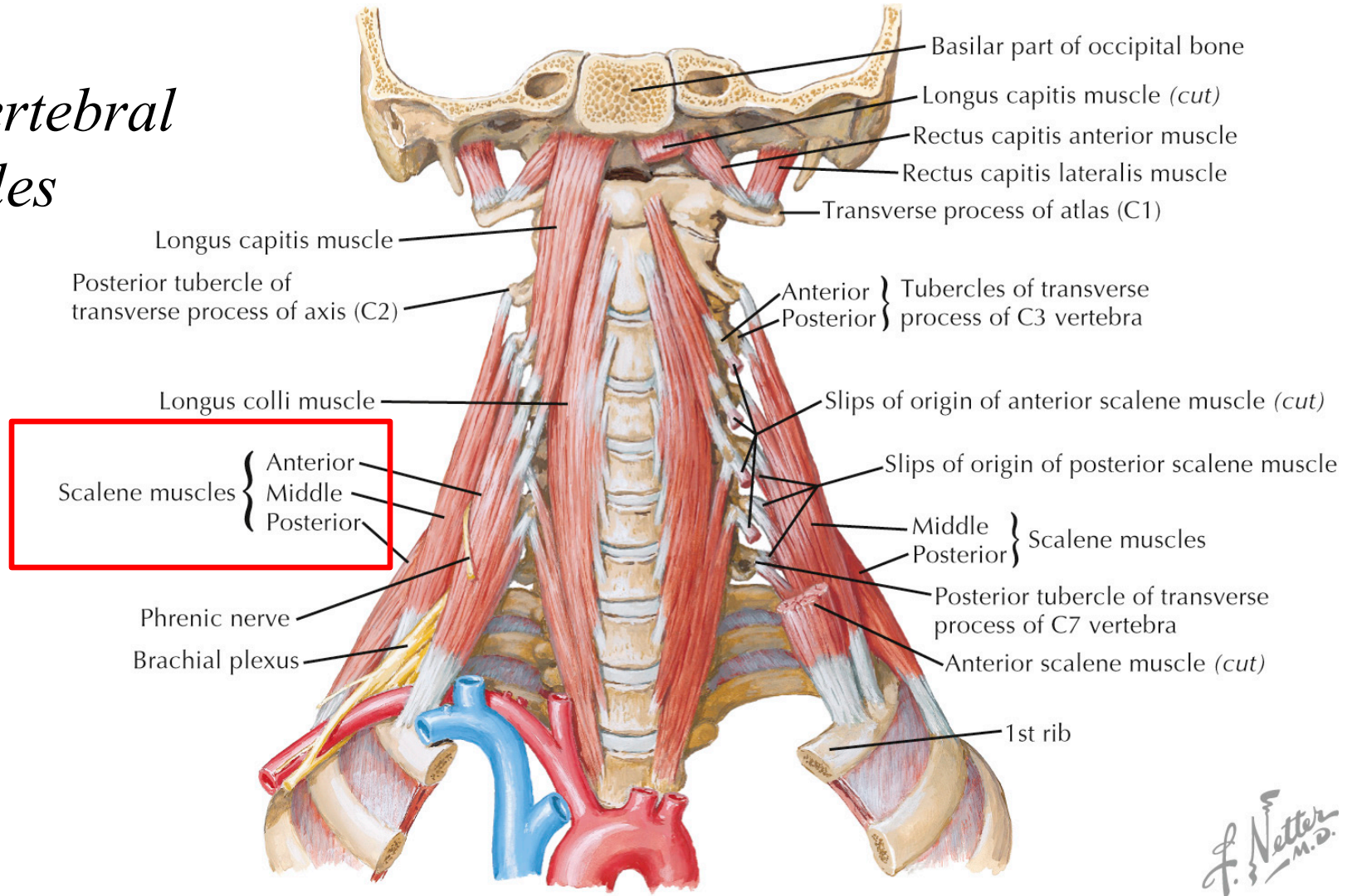


# Root of the neck



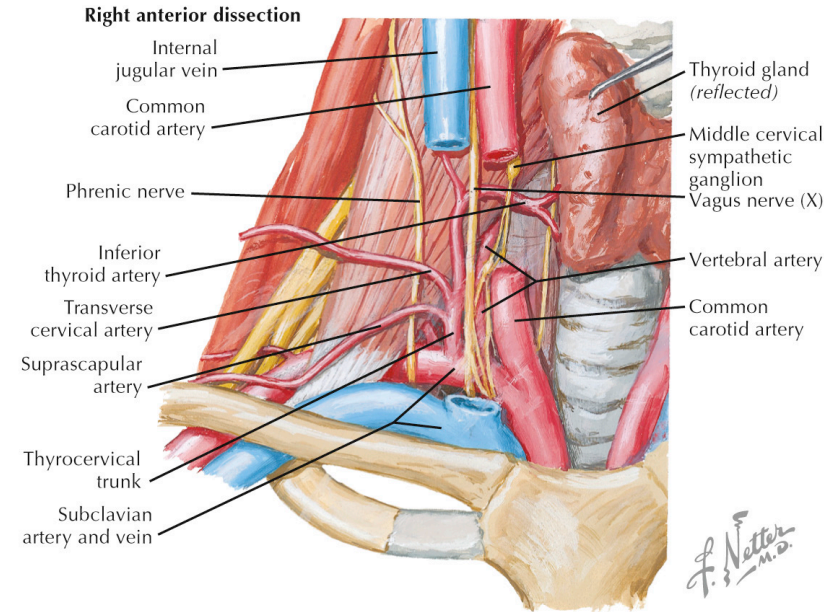
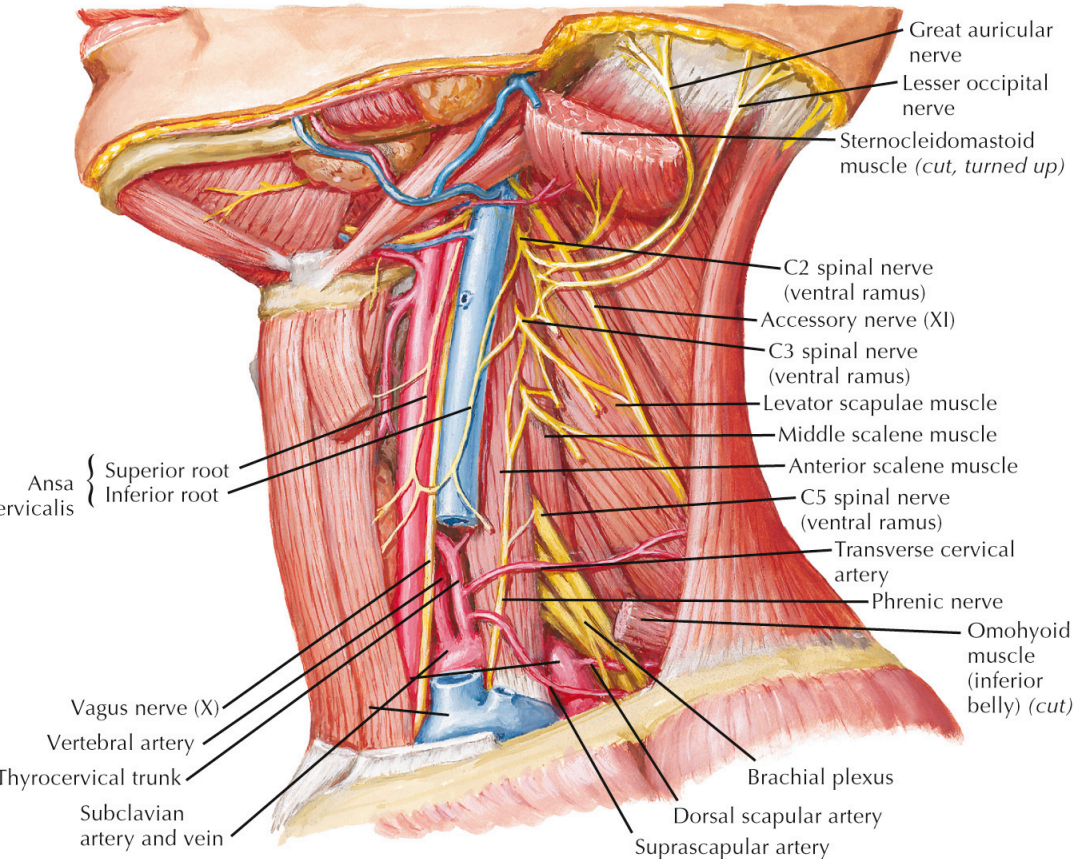
(A) Anterior view

# Prevertebral muscles

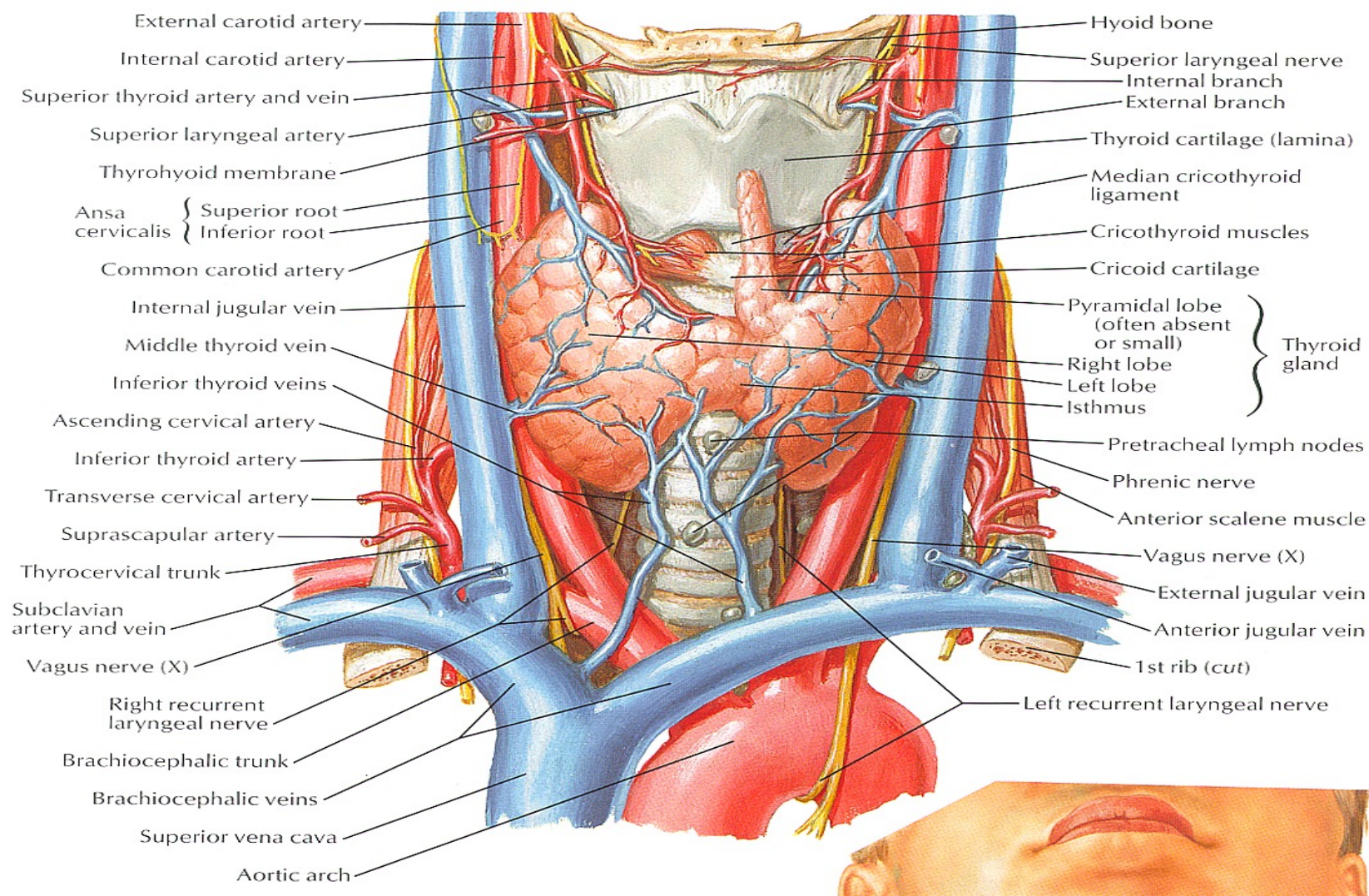




# Major contents of the root of the neck

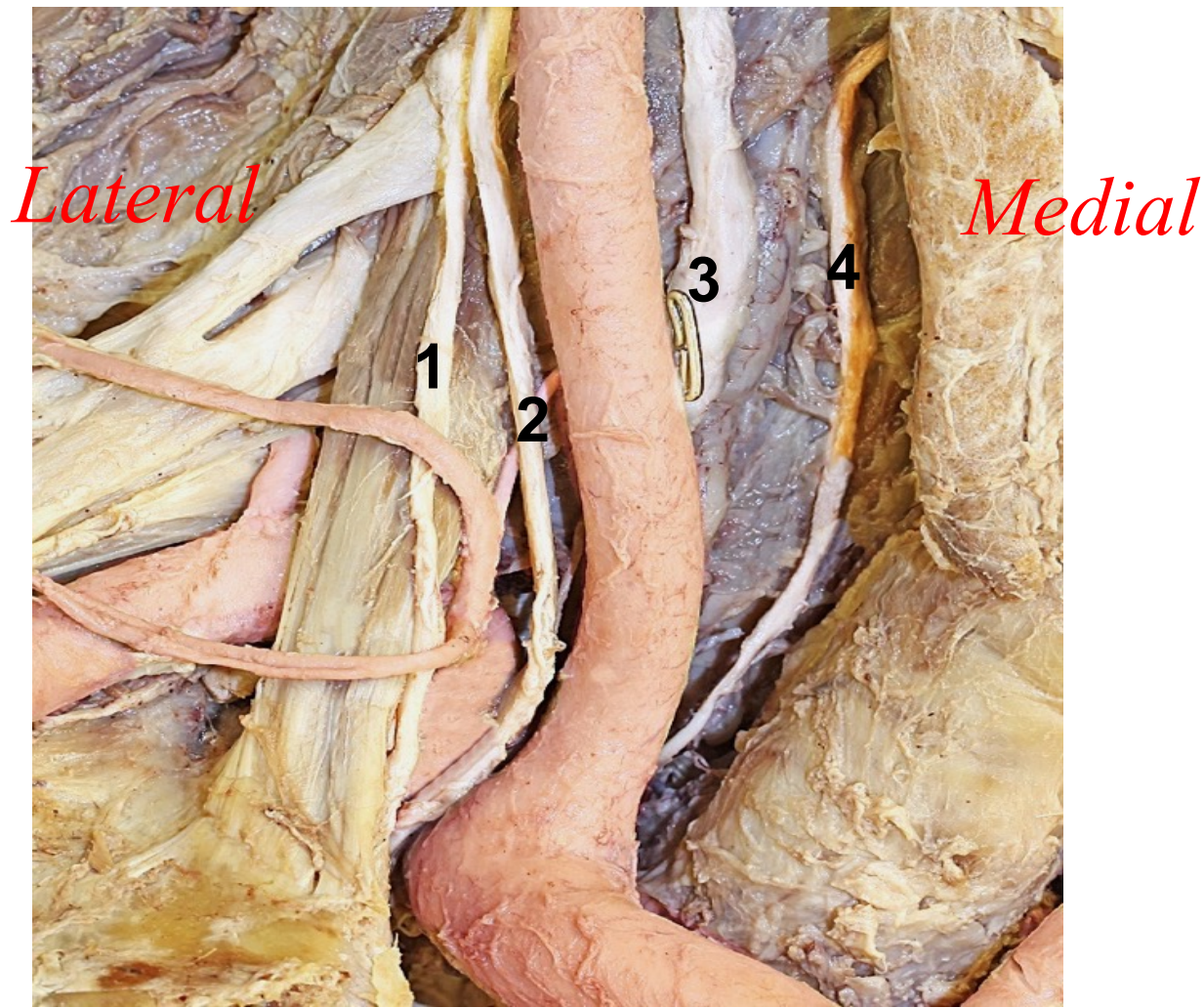






Right side  
posterior triangle

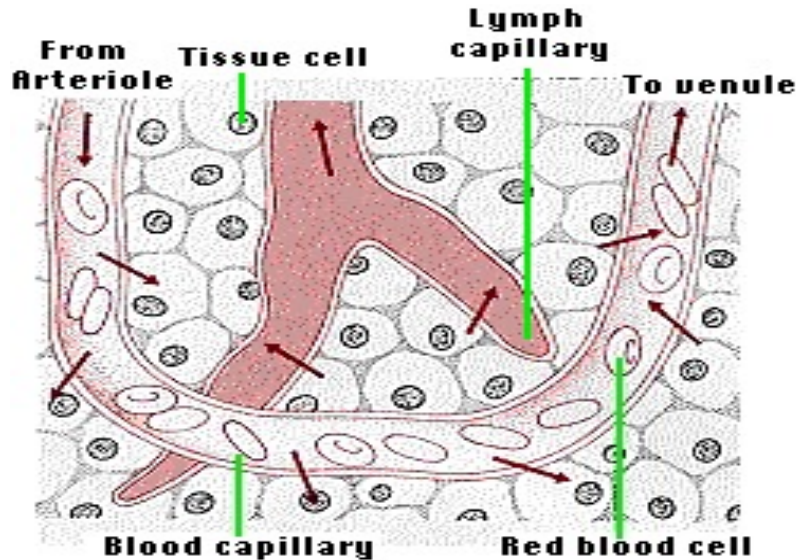
1. Phrenic nerve
2. Vagus nerve
3. Cervical Sympathetic trunk
4. Recurrent laryngeal nerve





# Review of lymph formation:

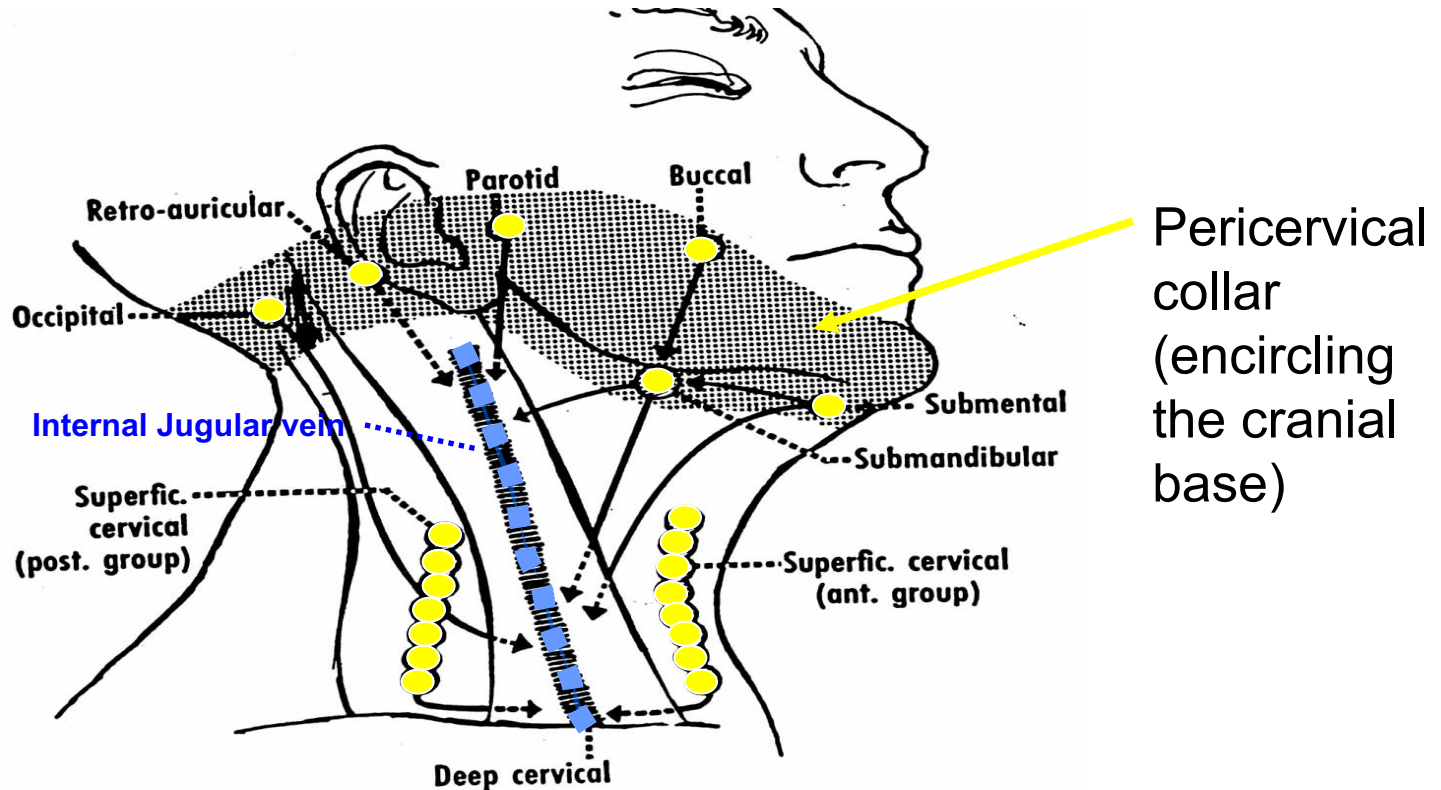
- Blood passes through capillaries
- Net loss of fluid into extracellular space
- Fluid moves into tiny lymph capillaries, bringing **cellular debris and antigenic material** into lymphatic circulation, where it is captured in the **lymph nodes**



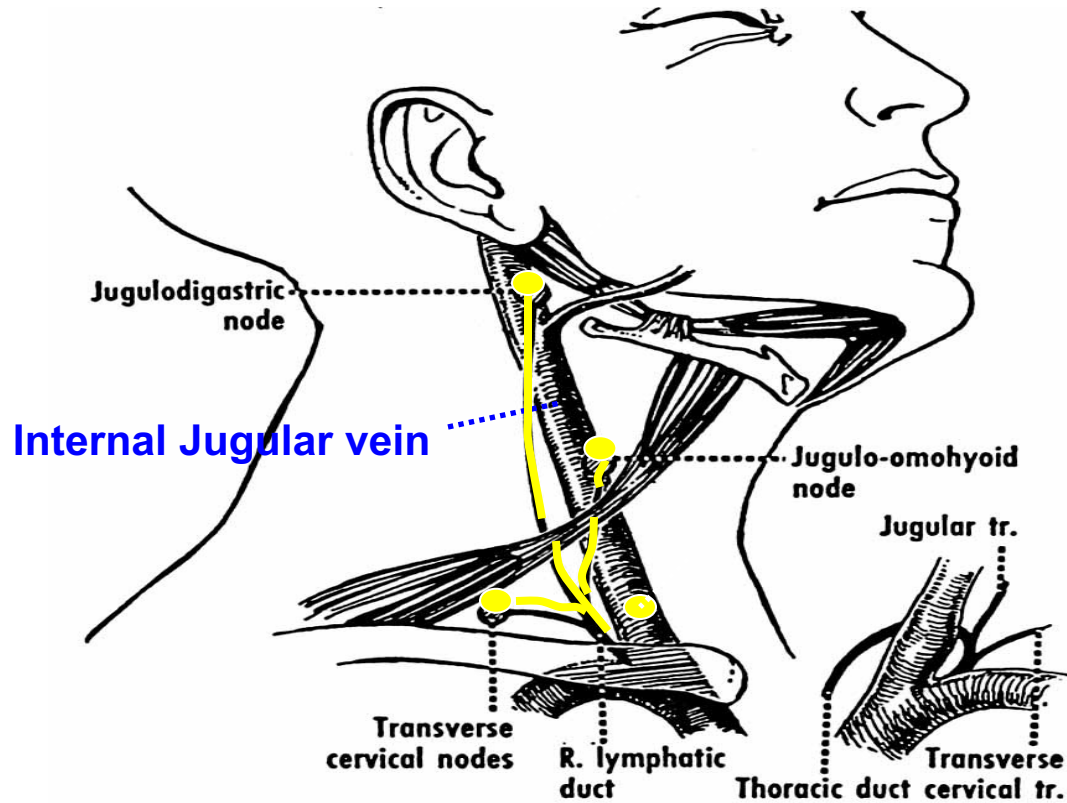


# Lymphatics of Head & Neck

## Superficial Lymphatics



# Deep Cervical Lymphatics



Superficial parotid nodes  
(deep parotid nodes  
deep to and within  
parotid gland)

Subparotid node

Facial nodes  
Nasolabial  
Buccinator

Mandibular  
nodes

Submandibular  
nodes

Submental  
nodes

Suprahyoid node

Superior deep lateral cervical  
(internal jugular) nodes

Superior thyroid nodes

Juguloomohyoid node

Anterior deep cervical  
(pretracheal and thyroid) nodes  
(deep to infrahyoid muscles)

Anterior superficial cervical  
nodes (anterior jugular nodes)

Jugular trunk

Supraclavicular nodes

Subclavian trunk and node

Occipital nodes

Mastoid nodes

Sternocleidomasto  
nodes

Superior lateral  
superficial cervical  
(external jugular)  
node

Jugulodigastric node

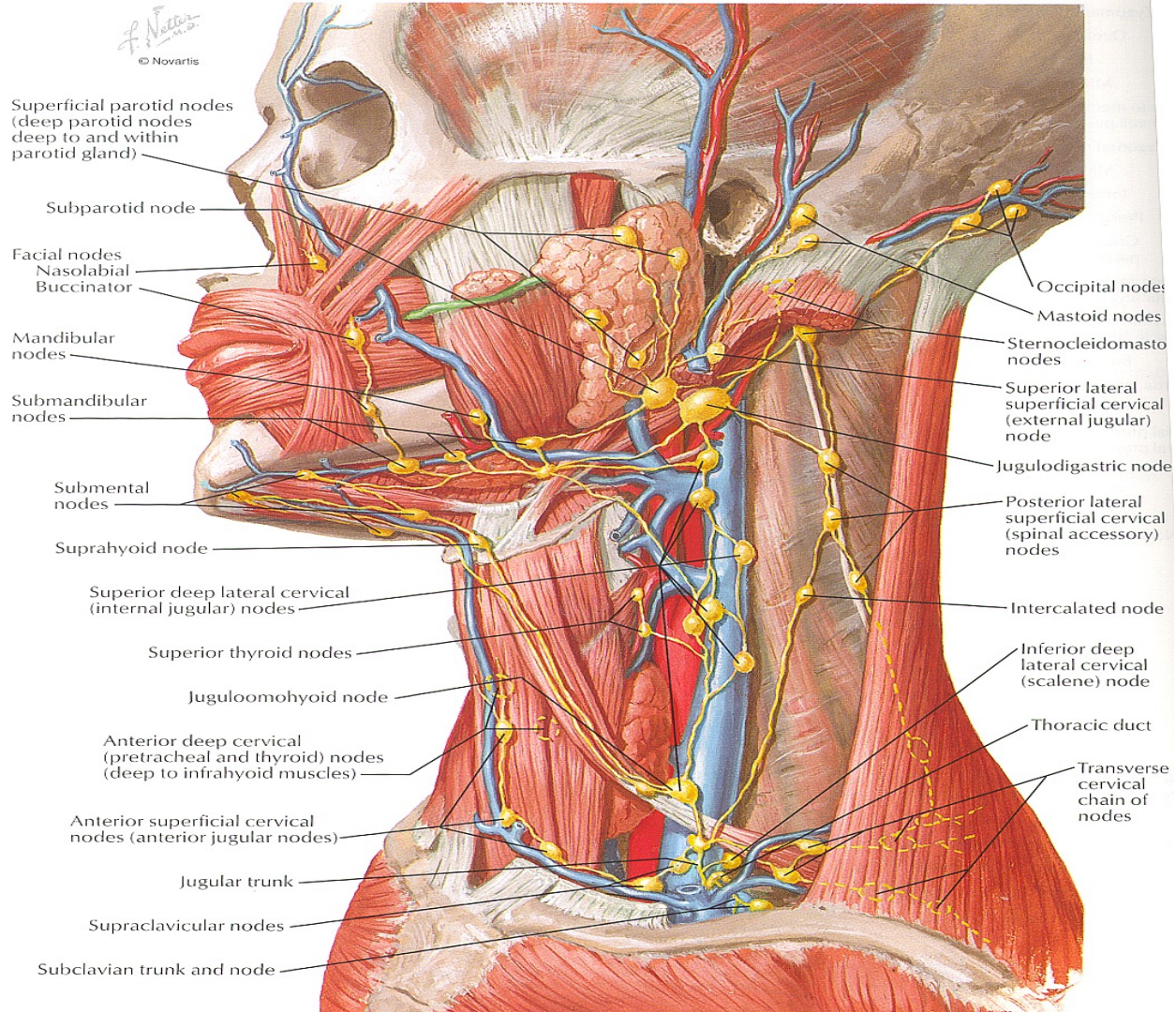
Posterior lateral  
superficial cervical  
(spinal accessory)  
nodes

Intercalated node

Inferior deep  
lateral cervical  
(scalene) node

Thoracic duct

Transverse  
cervical  
chain of  
nodes





# Lymphatics:

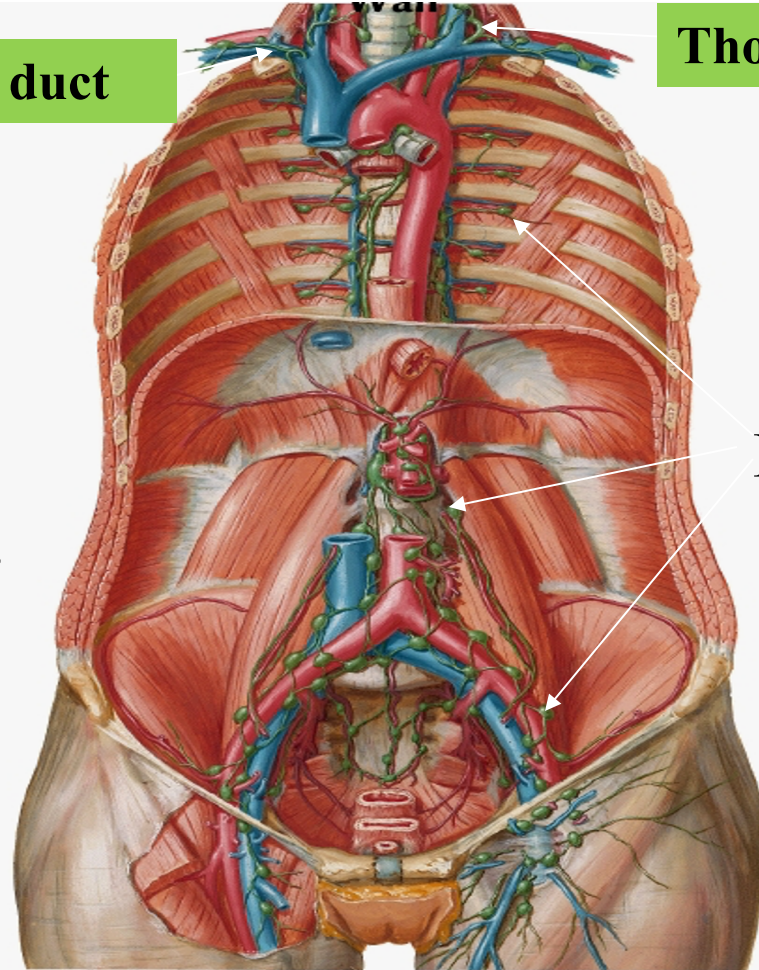
## R. Lymphatic duct

**Thoracic duct** receives lymph from the lower extremities, abdomen, left upper extremity, left chest, left side of the head & neck.

**Right lymphatic duct** receives lymph from the right chest, right upper extremity and right side of the head and neck

## Thoracic duct

Lymph nodes



# Cervical Fasciae

## A. Superficial

### 1. Superficial cervical fascia

## B. Deep

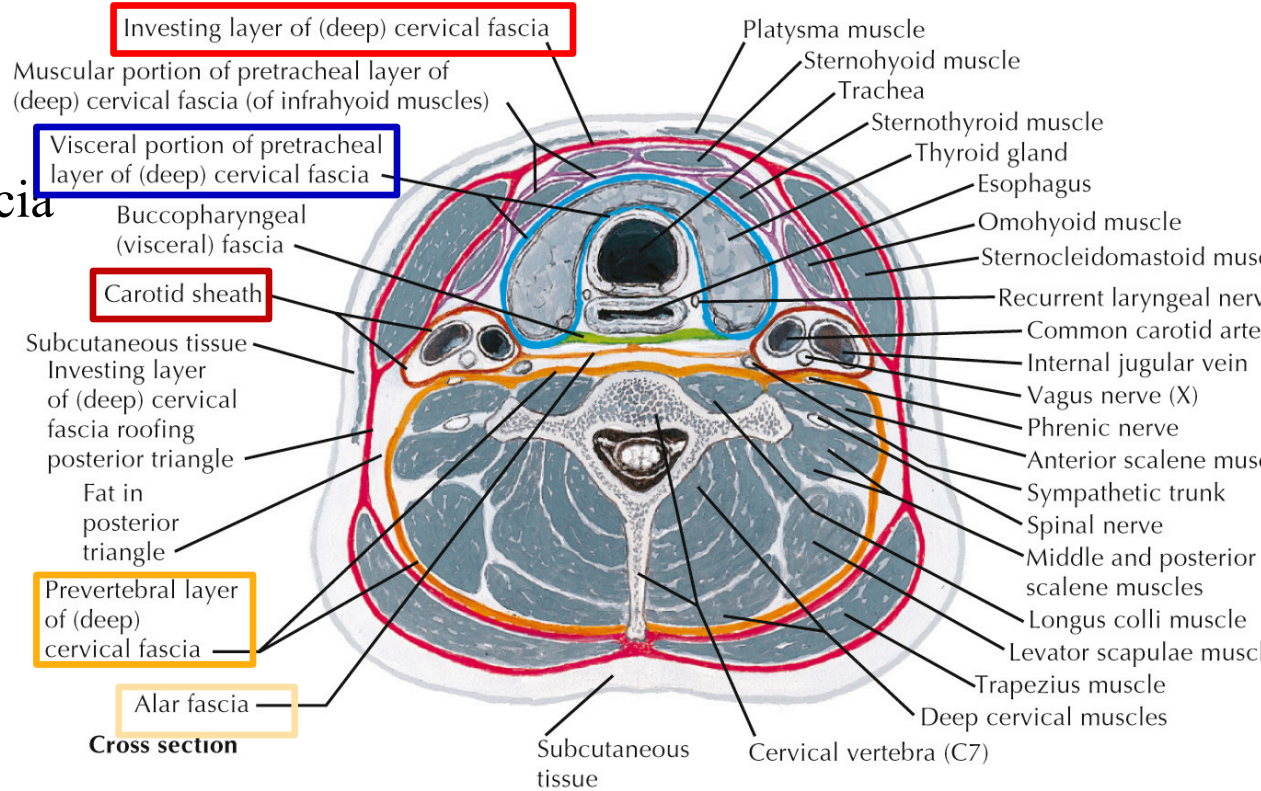
### 1. Investing layer of deep cervical fascia

### 2. Cervical visceral fascia (pretracheal fascia)

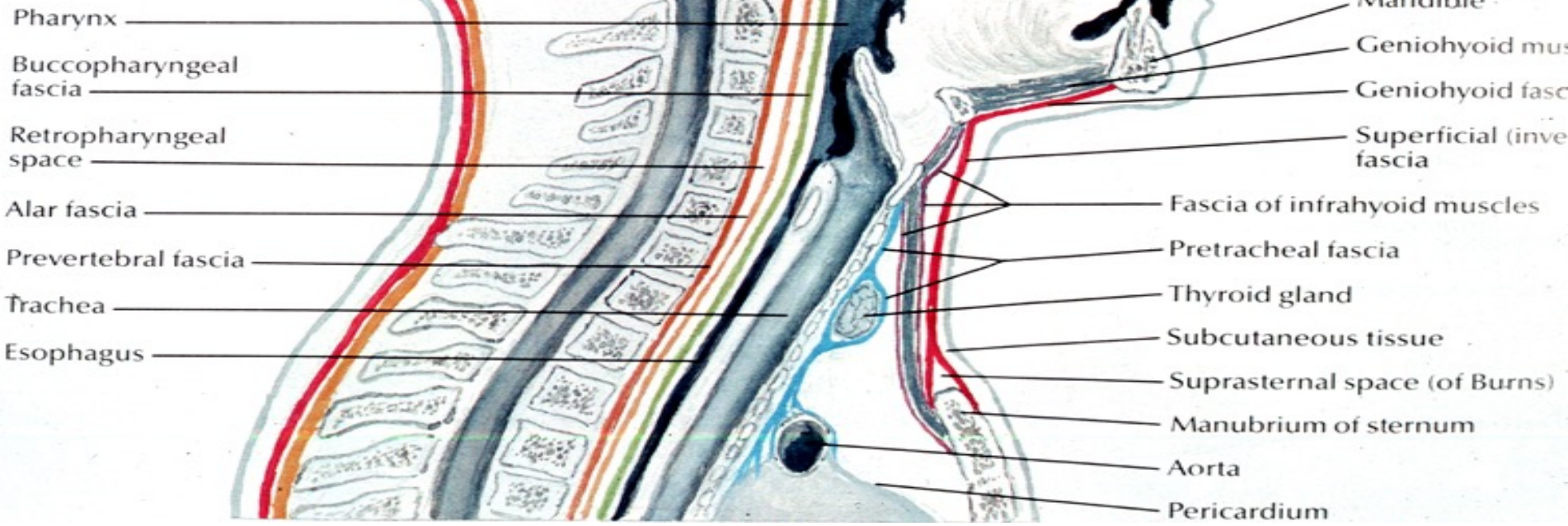
### 3. Alar fascia

### 4. Carotid sheath

### 5. Prevertebral fascia



## Sagittal section

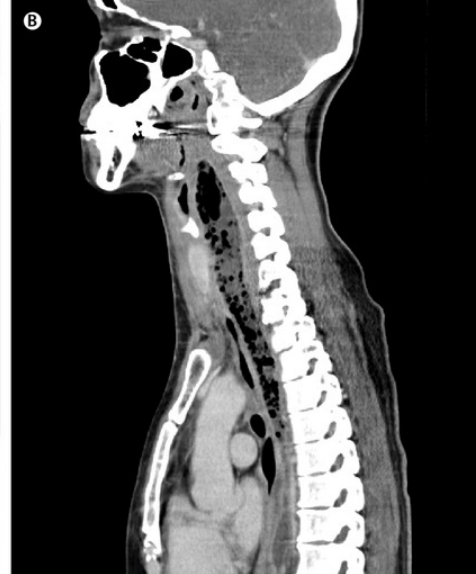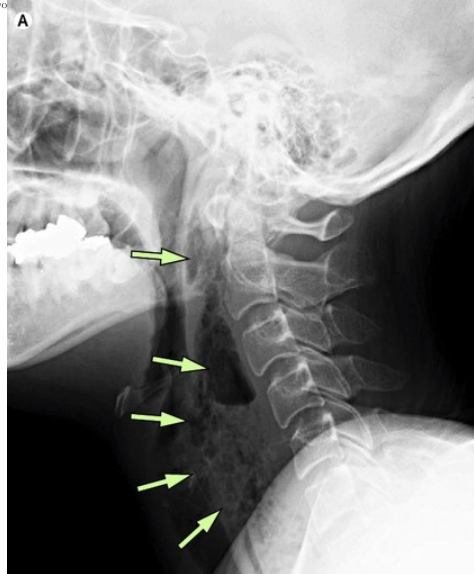
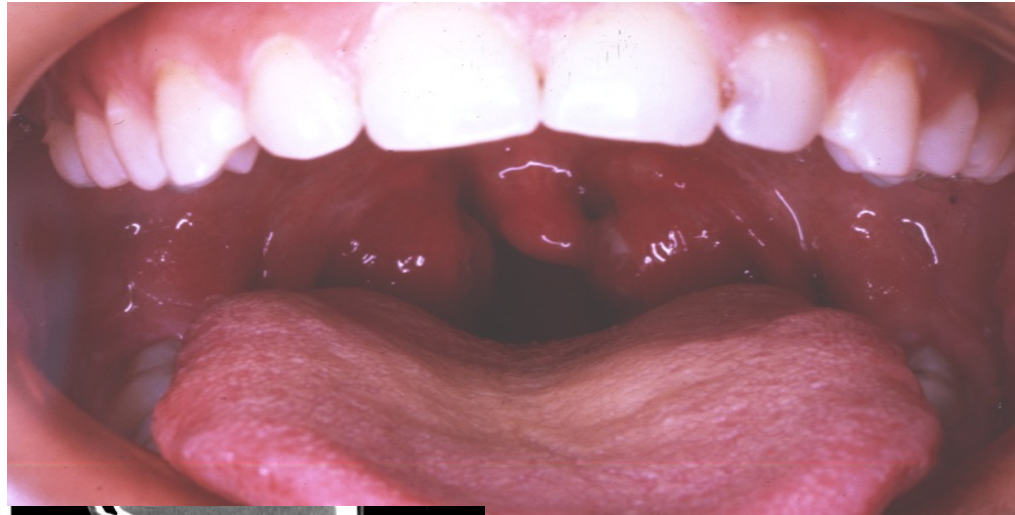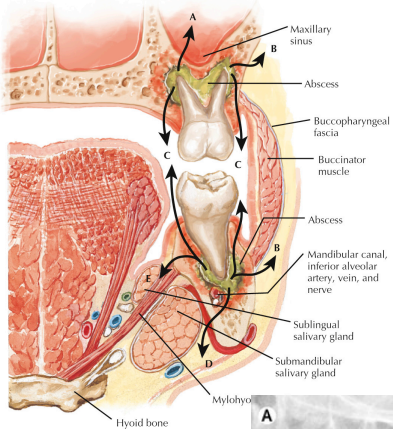




# Spread of odontogenic infection

Coronal section posterior to 1st molar tooth (anterior view)  
Arrows indicate possible paths of infection

- A Maxillary sinus
- B Buccal space
- C Oral cavity
- D Submandibular space
- E Sublingual space



*Retropharyngeal space involvement and compromised airway*